

## Impacts of curcumin on the healing procedure of eye cataracts in a rabbit model

Babak Olia<sup>1</sup>, Farrokhreza Kabir<sup>1\*</sup>, Siamak Mashhadi Rafiei<sup>2</sup>

1. Department of Radiology, Faculty of Veterinary Medicine, Science and Research Branch, Islamic Azad University, Tehran, Iran

2. Department of Small Animal Internal Medicine, Faculty of Veterinary Medicine, Science and Research Branch, Islamic Azad University, Tehran, Iran

\* Corresponding author's E-mail: frkabir@gmail.com

### ABSTRACT

Curcumin is a natural antioxidant agent derived from turmeric. The present survey assessed the anti-cataract effect of curcumin on experimentally induced cataracts in rabbit models. Twenty-four healthy rabbits were selected, numbered, and kept individually in separate cages for 2 weeks with routine feeding. Clinical examinations were done to assess the rabbit's eye health. Up to cataract formation, all rabbits received 0.1% sodium selenite (1 mg kg<sup>-1</sup> body weight subcutaneously). Then, rabbits were classified into four groups: control group I (without any oral treatment), control II (with oral normal saline), treatment I (oral consumption of commercial curcumin), and treatment II (oral consumption of vitamin E). Curcumin, vitamin E, and normal saline were fed to rabbits 3 times a day for 20 days at a rate of 15 mg kg<sup>-1</sup> body weight each time. Then, during ultrasound, the diameters of the anterior capsule of the lens, the posterior capsule of the lens, and the anterior-posterior of the lens were evaluated. Examination with slit lamp bio-microscopy was also done once every 3 days. Injection of 1 mg kg<sup>-1</sup> of body weight every 72 h three times caused rabbits to survive for more than a month, and the cataract was created. An increase in the thickness of the lens anterior and posterior capsules could be seen and measured from the 4<sup>th</sup> day, and this increase continued until the 12<sup>th</sup> day and did not change until the last day of the study. Sodium selenite caused an elevation in the diameters of the lens anterior, posterior, and anterior-posterior capsules. On the 20<sup>th</sup> day of the experiment, the lowest diameter of the anterior, posterior, and anterior-posterior capsules was obtained for rabbits of treatment I (Curcumin; 0.063 ± 0.002, 0.065 ± 0.002, and 0.598 ± 0.02 cm, respectively). Statistically significant differences were obtained for the diameter of the lens capsules between treatment I and control and treatment II (*p* < 0.05). The administration of oral curcumin (1 mg kg<sup>-1</sup> body weight 3 times a day for 20 days) significantly inhibited eye cataracts induced by sodium selenite in rabbit models. Rendering the edible route of curcumin and its beneficial effects, as well as synthesizing edible drugs based on curcumin for treating eye cataracts has been recommended.

**Keywords:** Curcumin, Vitamin E, Cataract, Rabbit, Ultrasonography.

**Article type:** Research Article.

### INTRODUCTION

Rabbit is a well-known house pet with easy maintenance, low food expectations, and low holding costs. Rabbits are very popular among people globally (Mapara *et al.* 2012). It is also a good animal model for medical experiments (Del Amo & Urtti 2015). Rabbits have comparatively large eyes with similar anatomical features to humans, such as internal structures, eyeball size, optical system, conjunctiva cavity volume, and biochemical and biomechanical properties (Badaro *et al.* 2022). It is the most routinely utilized model for experimental ophthalmology (Zernii *et al.* 2016). Good accessibility, the economy of maintenance and acquisition, general

tractability, and comparatively large protuberant globes make rabbit appropriate models in ophthalmology (Singh *et al.* 2021). Curcumin (diferuloylmethane) is a yellow polyphenol originating from *Curcuma longa* L. rhizome and mainly turmeric (Al-Musawi 2022; Okhovatfard & Rezazadeh 2023). It is familiar with its high antioxidant effects against free radicals and is mainly used as a species in Iranian medicine (Nunes *et al.* 2024). It is also applied as an ointment, energy beverages, soaps, capsules, cosmetics, tablets, and folk application in other countries, especially China, South Africa, Japan, India, Pakistan, Korea, Thailand, and even the United States (Rathore *et al.* 2020). It has highly beneficial effects on wounds, allergies, cancer, sinusitis, inflammation, asthma, and cardiac and hepatic function (Hewlings & Kalman 2017). Lost in the eye lens transparency is called cataract (Lam *et al.* 2015). There are about 45 million blind people in the world, and around half of them lose their vision due to cataracts (Meacock *et al.* 2003). Surgery is the most commonly used treatment for this disease, and most people regain their vision immediately after surgery. However, a considerable number of patients lose their sight again several months to several years after surgery due to posterior capsule opacification (PCO; Wu *et al.* 2018; Fichtner *et al.* 2021). As free radicals, particularly hydroxyl radical (OH $\cdot$ ) superoxide anion (O $^{2-}$ ), nitric oxide (NO), and hydrogen peroxide (H $_2$ O $_2$ ) are responsible for the cataract pathogenicity, the application of antioxidants may recover patients and inhibit the expansion of the disease (Kulbay *et al.* 2024). In this regard and rendering the edible nature of curcumin, it has been successfully tested as a safe and natural antioxidant for eye disease healing (López-Malo *et al.* 2020). As a result, the present research was conducted to assess oral curcumin's healing effects in rabbit models' experimentally-induced cataracts using the ultrasonographic examination.

## MATERIALS AND METHODS

### Chemical reagents

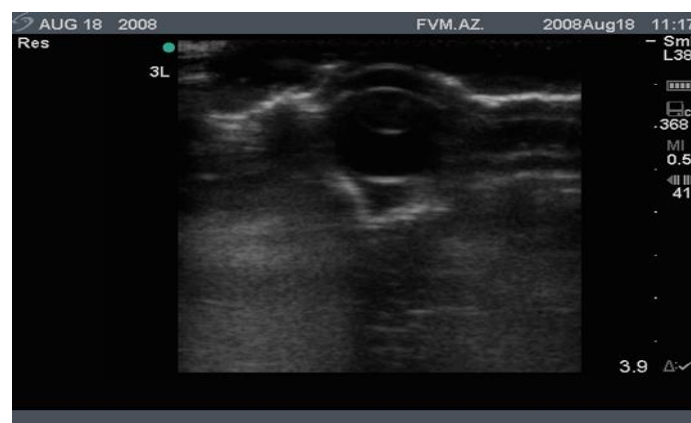
Sodium selenite (99.3% purity) was purchased from Merck Company (Merck, Germany), vitamin E tablet from Rahadaru Company (Rahadaru, Isfahan, Iran) and curcumin from the Dineh Company (Dineh, Tehran, Iran).

### Animals

Twenty-four one-year-old male healthy white New Zealand rabbits (Albino rabbit) weighing  $2200 \pm 400$  g were purchased from the Pasteur Institute (Tehran, Iran). Then, the rabbits were transferred to the holding place, where they were subjected to clinical examination (general examination and health confirmation). Afterward, the animals were weighed, anti-parasitic tablets were administered, and other information was completed in special forms individually for each rabbit. Animals were kept on a fresh diet, water, appropriate temperature, and normal lighting conditions.

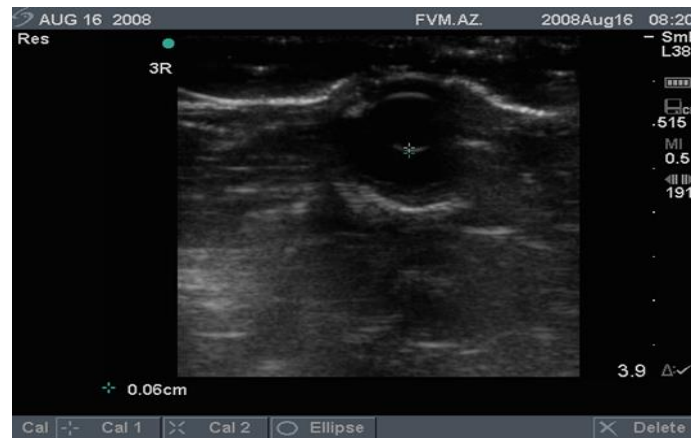
### Preliminary examinations

Rabbits were accurately numbered and kept individually in separate cages for two weeks, then were fed with carrots, apples, bread, and special rabbit food (Pasteur Institute, Tehran, Iran). Clinical examinations were performed to assess the rabbit's eye health. So that, the rabbit's eyes were assessed by an ophthalmoscope, a slit-lamp biomicroscope equipped with a digital camera, and regular inspection of the external parts. Additionally, a fluorescent strip was used to assess the presence of probable scars or wounds on the cornea. Furthermore, the amounts of teardrops by eye strip and lens opacity were also checked. All examinations were carried out at the Ophthalmology Research Center, Faiz Hospital, Isfahan, Iran.



**Fig. 1.** Normal ultrasonographic image of the rabbit eye.

After ensuring that the eyes are healthy, the normal shape of the cornea, the normal size of the lens, and other eye structures were evaluated using ultrasonography. Ultrasound examination was performed only by physically restraining the animal without general or local anesthesia. Corneal ultrasound was carried out using sufficient amounts of ultrasound gel by placing the transducer (10 MHz) horizontally on the cornea. All measurements were performed and recorded by an expert, and images were taken to align the cornea, anterior lens capsule, posterior lens capsule, and optic disc. After each ultrasonography, the rabbit's eyes were washed with warm normal saline solution for 45 s. Fig. 2 shows the measurement of the posterior lens capsule.



**Fig. 2.** Measurement of the posterior lens capsule.

## Experiment

Then the rabbits were divided into four groups (6 rabbits in each group) (Table 1).

**Table 1.** Experimental groups of rabbits.

Groups	Sodium selenite	Curcumin	Vitamin E	Normal saline
Control I	+	-	-	-
Control II	+	-	-	+
Treatment I	+	+	-	-
Treatment II	+	-	+	-

After accurately weighing the rabbits, sodium selenite was dissolved in injectable normal saline to a concentration of 0.1% and administered subcutaneously (SC) at the back of the neck ( $1 \text{ mg kg}^{-1}$  body weight) of all rabbits. The groups include the control group I (without any oral treatment), the first treatment group (oral consumption of commercial curcumin), the second treatment group (oral consumption of vitamin E), and the control group II (oral consumption of normal saline). The gavage tube was used to feed medicinal substances. Curcumin, vitamin E, and normal saline were fed to rabbits three times a day for 20 days by gavage tube at a rate of  $15 \text{ mg kg}^{-1}$  body weight each time. Then, during ultrasound, the diameters of the anterior, posterior and anterior-posterior capsules of the lens were evaluated. Examination with slit lamp biomicroscopy was also done once every three days, and grading of cataracts was performed according to Table 2. All tests continued for 20 days, and on the 20<sup>th</sup> day, the final grading was carried out for each sample and recorded separately for each group. Measurements were performed on days 0, 5, 10, 15, and 20 of the experiment (Baha'a & Alzubaidy 2014).

**Table 2.** Grading of cataract caused by subcutaneous injection of sodium selenite in rabbits.

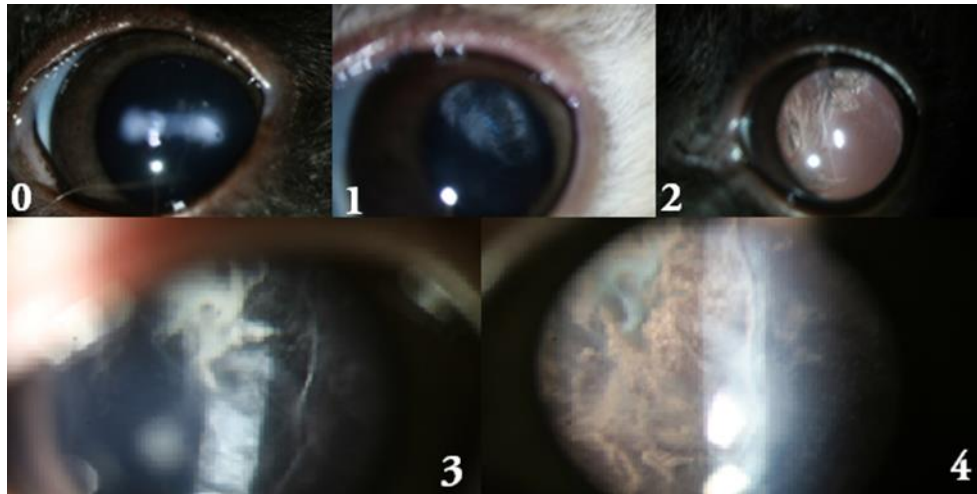
Cataract grade	Lens status
0	No opacity
1	Localized PCSS* lower than 50% of lens
2	50% of lens < PCSS < 75% of lens
3	PCSS > 75% of lens
4	Cortical cataract with PCSS > 75% of lens

\*Posterior Subcapsular Cataract.

Fig. 3 shows the cataract grading in rabbit's eyes after SC injection of sodium selenite.

## Data analysis

Data were transferred to Excel software (Shahreza 2022). All measurements were carried out in triplicate. Statistical analysis was performed using SPSS 21.0 statistical software and ANOVA statistical test, and the differences were significant at  $p$ -values < 0.05 (Shahreza *et al.* 2022).



**Fig. 3.** Grading in rabbit's eyes after SC injection of sodium selenite. Each number shows the cataract grade based on Table 2.

## RESULTS

### Findings of slit-lamp biomicroscopic and ultrasonography

The results obtained from this study showed that the injection of  $1.5 \text{ mg kg}^{-1}$  or more sodium selenite in a single injection caused acute poisoning and killed rabbits in less than 24 h, but by injection of  $1 \text{ mg kg}^{-1}$  every 72 h for three times, they survived for more than 1 month and the cataract was developed in rabbits. Examination using a slit-lamp biomicroscope showed that cataracts were visible in all rabbits of the control groups up to the first degree from the 4<sup>th</sup> day, up to the second degree from the 8<sup>th</sup> day, and up to the third degree from the 11<sup>th</sup> day (100%). Afterward, the cataract remained until the end of the investigation. Based on the ultrasonographical findings, the increase in the thickness of the anterior and posterior capsules of the lens could be seen and measured from the 4<sup>th</sup> day. This increase continued until the 12<sup>th</sup> day and did not change until the last day of the study.

### Assessment of the effects of curcumin and vitamin E on cataract

Table 3 shows the mean diameter of the lens's anterior, posterior, and anterior-posterior capsules in rabbits of control and treatment groups on day 0 of the experiment. The mean diameters of the lens's anterior, posterior, and anterior-posterior capsules in rabbits of all groups were relatively equal.

**Table 3.** The mean diameter of the anterior, posterior, and anterior-posterior capsule of the lens in rabbits of control and treatment groups on day 0 of the experiment.

Groups	Mean diameters of the capsule in the lens (cm)			Findings of the slit-lamp biomicroscopic
	Anterior capsule	Posterior capsule	Anterior-posterior	
Control I	$0.035 \pm 0.002^a$	$0.035 \pm 0.002^a$	$0.583 \pm 0.02^a$	Completely healthy
Control II	$0.038 \pm 0.001^a$	$0.038 \pm 0.001^a$	$0.585 \pm 0.01^a$	
Treatment I	$0.034 \pm 0.002^a$	$0.034 \pm 0.002^a$	$0.582 \pm 0.02^a$	
Treatment II	$0.036 \pm 0.001^a$	$0.036 \pm 0.001^a$	$0.584 \pm 0.03^a$	

\*Dissimilar letters in each column showed statistically significant differences about  $P < 0.05$ .

Table 4 shows the mean diameter of the lens's anterior, posterior, and anterior-posterior capsules in rabbits of control and treatment groups on day 5 of the experiment. Experimentally induced cataracts using sodium selenite caused an increase in the diameters of these capsules. The mean diameter of these capsules increased after 5 days in all studied groups. The lowest diameter of these capsules was obtained for rabbit samples of the treatment I (Curcumin) ( $0.051 \pm 0.002$ ,  $0.052 \pm 0.001$ , and  $0.577 \pm 0.01$  cm, respectively). Statistically significant differences were obtained for the diameter of the lens capsules between treatment I and both control groups ( $p < 0.05$ ). Additionally, statistically significant differences were obtained for the diameter of the lens capsules between treatment II and control groups ( $P < 0.05$ ). The achieved data between treatment I (curcumin) and treatment II (vitamin E) groups were only statistically significant for the diameter of the anterior-posterior capsule ( $p < 0.05$ ). Slit-lamp examination showed the first grade cataract in rabbits of control groups and also first grade cataract in some cases of the treatment II. White rabbits in the treatment I were clinically healthy in the slit-lamp examination. Table 5 shows the mean diameter of the anterior, posterior, and anterior-posterior lens capsules in rabbits of control and treatment groups on day 10 of the experiment. The mean diameter of these capsules also increased

after 10 days in all studied groups. The lowest diameter of these capsules was obtained in treatment I (Curcumin;  $0.055 \pm 0.002$ ,  $0.056 \pm 0.002$ , and  $0.587 \pm 0.03$  cm, respectively). Statistically significant differences were obtained for the diameter of the lens capsules between treatment I and both control groups ( $p < 0.05$ ). Additionally, statistically significant differences were observed in the diameter of the lens capsules between treatment II and the control groups ( $p < 0.05$ ). The achieved data between treatment I (curcumin) and treatment II (vitamin E) were only statistically significant different in the diameter of the anterior-posterior capsule ( $p < 0.05$ ). Slit-lamp examination showed the 1<sup>st</sup> to 2<sup>nd</sup> grade cataracts in rabbits of control groups and 1<sup>st</sup> grade cataracts in some cases of the treatment groups.

**Table 4.** The mean diameter of the anterior, posterior, and anterior-posterior capsule of the lens in rabbits of control and treatment groups on day 5 of the experiment.

Groups	Mean diameters of the capsule in the lens (cm)			Findings of the slit-lamp biomicroscopic
	Anterior capsule	Posterior capsule	Anterior-posterior	
Control I	$0.058 \pm 0.001^{a*}$	$0.059 \pm 0.002^a$	$0.619 \pm 0.02^a$	1 <sup>st</sup> grade cataract
Control II	$0.056 \pm 0.001^a$	$0.057 \pm 0.001^a$	$0.589 \pm 0.01^b$	1 <sup>st</sup> grade cataract
Treatment I	$0.051 \pm 0.002^b$	$0.052 \pm 0.001^b$	$0.577 \pm 0.01^c$	Completely healthy
Treatment II	$0.054 \pm 0.001^{ab}$	$0.054 \pm 0.001^b$	$0.581 \pm 0.02^b$	1 <sup>st</sup> grade cataract in some cases

\*Dissimilar letters in each column showed statistically significant differences at  $p < 0.05$ .

**Table 5.** The mean diameter of the anterior, posterior, and anterior-posterior capsule of the lens in rabbits of control and treatment groups on day 10 of the experiment.

Groups	Mean diameters of the capsule in the lens (cm)			Findings of the slit-lamp biomicroscopic
	Anterior capsule	Posterior capsule	Anterior-posterior	
Control I	$0.064 \pm 0.001^{a*}$	$0.067 \pm 0.001^a$	$0.621 \pm 0.01^a$	1 <sup>st</sup> to 2 <sup>nd</sup> grade cataract
Control II	$0.065 \pm 0.002^a$	$0.067 \pm 0.001^a$	$0.621 \pm 0.01^a$	1 <sup>st</sup> to 2 <sup>nd</sup> grade cataract
Treatment I	$0.055 \pm 0.002^b$	$0.056 \pm 0.002^b$	$0.587 \pm 0.03^c$	1 <sup>st</sup> grade cataract in some cases
Treatment II	$0.060 \pm 0.001^b$	$0.061 \pm 0.002^b$	$0.595 \pm 0.03^b$	1 <sup>st</sup> grade cataract in some cases

\*Dissimilar letters in each column showed statistically significant differences at  $p < 0.05$ .

Table 6 shows the mean diameter of the lens's anterior, posterior, and anterior-posterior capsules in rabbits of the control and treatment groups on day 15 of the experiment. The mean diameter of these capsules also increased after 15 days in all studied groups. The lowest diameter of these capsules was observed in treatment I (curcumin) ( $0.058 \pm 0.001$ ,  $0.060 \pm 0.001$ , and  $0.591 \pm 0.02$  cm, respectively). Statistically significant differences were observed in the diameter of these capsules between treatment I and both control groups ( $p < 0.05$ ). It was also true for treatment II and control groups ( $p < 0.05$ ). The achieved data between treatment I (curcumin) and treatment II (vitamin E) were only significantly different in the diameter of the anterior-posterior capsule ( $p < 0.05$ ). Slit-lamp examination showed 2<sup>nd</sup> to 3<sup>rd</sup> grade cataracts in rabbits of control groups, 1<sup>st</sup> grade in some cases of the treatment I, and also 1<sup>st</sup> grade in treatment II.

**Table 6.** The mean diameter of the anterior, posterior, and anterior-posterior capsule of the lenses in rabbits of control and treatment groups on day 15 of the experiment.

Groups	Mean diameters of the capsule in the lens (cm)			Findings of the slit-lamp biomicroscopic
	Anterior capsule	Posterior capsule	Anterior-posterior	
Control I	$0.070 \pm 0.001^{a*}$	$0.072 \pm 0.003^a$	$0.630 \pm 0.02^a$	2 <sup>st</sup> to 3 <sup>rd</sup> grade cataract
Control II	$0.069 \pm 0.002^a$	$0.072 \pm 0.001^a$	$0.629 \pm 0.02^a$	2 <sup>st</sup> to 3 <sup>rd</sup> grade cataract
Treatment I	$0.058 \pm 0.001^b$	$0.060 \pm 0.001^b$	$0.591 \pm 0.02^c$	1 <sup>st</sup> grade cataract in some cases
Treatment II	$0.063 \pm 0.001^{ab}$	$0.065 \pm 0.001^b$	$0.602 \pm 0.01^b$	1 <sup>st</sup> grade cataract

\*Dissimilar letters in each column showed statistically significant differences at  $p < 0.05$ .

Table 7 shows the mean diameter of the lens's anterior, posterior, and anterior-posterior capsules in rabbits of control and treatment groups on day 20 of the experiment which increased in all studied groups. The lowest diameter of these capsules was observed in treatment I (Curcumin;  $0.063 \pm 0.002$ ,  $0.065 \pm 0.002$ , and  $0.598 \pm 0.02$  cm, respectively). Statistically significant differences were observed in their diameters between treatment I and both control groups ( $p < 0.05$ ). It was also true for treatment II and control groups ( $p < 0.05$ ). The achieved data between treatment I (curcumin) and treatment II (vitamin E) were only significantly different in the diameter of the anterior-posterior capsule ( $p < 0.05$ ). However, slit-lamp examination showed the occurrence of 1<sup>st</sup> to 2<sup>nd</sup> grade cataracts in all rabbits of the treatment II, while 1<sup>st</sup> grade cataracts in some cases of the treatment I. Rabbits of control groups showed 3<sup>rd</sup> grade cataracts.

**Table 7.** The mean diameter of the anterior, posterior, and anterior-posterior capsule of the lens in rabbits of control and treatment groups on day 20 of the experiment.

Groups	Mean diameters of the capsule in the lens (cm)			Findings of the slit-lamp biomicroscopic
	Anterior capsule	Posterior capsule	Anterior-posterior	
Control I	0.077 ± 0.001 <sup>a*</sup>	0.078 ± 0.002 <sup>a</sup>	0.639 ± 0.01 <sup>a</sup>	3 <sup>rd</sup> -grade cataract
Control II	0.075 ± 0.001 <sup>a</sup>	0.076 ± 0.002 <sup>a</sup>	0.637 ± 0.01 <sup>a</sup>	3 <sup>rd</sup> -grade cataract
Treatment I	0.063 ± 0.002 <sup>b</sup>	0.065 ± 0.002 <sup>c</sup>	0.598 ± 0.02 <sup>c</sup>	1 <sup>st</sup> grade cataract in some cases
Treatment II	0.069 ± 0.002 <sup>b</sup>	0.070 ± 0.002 <sup>bc</sup>	0.614 ± 0.01 <sup>b</sup>	1 <sup>st</sup> to 2 <sup>nd</sup> grade cataract

\*Dissimilar letters in each column showed statistically significant differences at  $p < 0.05$ .

## DISCUSSION

The application of curcumin as a potential antioxidant agent in rabbits with confirmed cataracts effectively inhibited cataract expansion compared to both control groups. Additionally, compared with the Vitamin E group, curcumin can significantly inhibit the increase in the length of the anterior-posterior capsule in treated rabbits on all days of the experiment. Curcumin was also effective in the finding of the slit-lamp biomicroscopic in the detection of cataract grades. Rabbits treated with curcumin only showed 1<sup>st</sup> grade cataracts even on day 20 of the experiment. The findings supported the inhibitory effects of curcumin on cataract expansion in rabbit models. Curcumin defers cataract progression through several pathways, including a change in lipid peroxidation, reduction in glutathione (GSH), protein carbonyl, and antioxidant enzyme activities, as well as decreasing lens proteins' solubilization and aggregation (Suryanarayana *et al.* 2005). The effect of curcumin on selenite-induced cataracts in the Rat model was studied by Radha *et al.* (2012). They found that curcumin is beneficial against selenite-induced cataracts by reversing the activity of antioxidant enzymes and calcium homeostasis to near-normal levels in the lens. In another survey (Awasthi *et al.* 1996), the lenses of rat groups treated with curcumin (oral) were more resistant to opacification induced by 4-HNE. Similarly, curcumin repressed free radical generation, cataract formation, and oxidative stress, in addition to inhibiting inducible nitric oxide synthase (iNOS) expression (Manikandan *et al.* 2009). Manikandan *et al.* (2010) reported that dietary curcumin prevented selenium-induced Ca<sup>2+</sup> ATPase activation and inhibited cataracts in rat models. Dietary curcumin prevented oxidative damage and delayed cataract development by attenuating xanthine oxidase enzyme activity, lipoperoxides (LPO), and lipid peroxidation as well as increasing superoxidase dismutase and catalase enzyme activity (Padmaja & Raju 2004). In this regard, Grama *et al.* (2013) mentioned that oral nano-curcumin was more effective in delaying rat diabetic cataracts, attributed to its intervention ability to insolubilization of protein, protein glycation, polyol pathway, crystallin distribution, and oxidative stress. Awasthi *et al.* (1996) were the initial persons who reported the curcumin anticataract effects. They established the curcumin's protective nature toward the toxic lipid peroxidation end product, 4-hydroxy two trans nonenal (4-HNE) which can cause cataracts. Curcumin administration activates the formation of glutathione S-transferases (GSTs) isoenzyme in rats, which aided in the 4-HNE conjugation to glutathione, thereby leading to 4-HNE detoxification and rendering its. Compared to rabbits treated with vitamin E, curcumin more effectively controlled the changes in the cataract progression and the lens's anterior and posterior capsules and anterior-posterior length. Vitamin E mitigated steroid-induced cataractogenesis by safeguarding the lenses from oxidative harm and functional decline of their membranes. Nevertheless, wide-ranging experimental research has reliably indicated that vitamin E does not confer cataract protection in humans (Zhuang *et al.* 2024). This finding may confirm parts of our results regarding the lower anti-cataract effects of vitamin E compared to curcumin. Our investigation certainly determined curcumin's anti-cataract effects. However, this research may be limited to the low number of examined rabbits, the absence of regional application of curcumin (as drops directly in the eye), and its comparison with other therapeutic agents used for cataract treatment.

## CONCLUSION

In conclusion, administration of oral curcumin (1 mg kg<sup>-1</sup> body weight three times a day for 20 days) significantly inhibited eye cataracts induced by sodium selenite in rabbit models compared to control groups. Additionally, the inhibitory effects of oral curcumin were significantly higher than those of oral Vitamin E administration. Rabbits treated with curcumin showed 1<sup>st</sup> grade cataracts in some cases after 10 days of exposure to sodium selenite, while other rabbits showed 1<sup>st</sup> grade cataracts on day 5 of the experiment. After 20 days of exposure to sodium selenite, only some of the rabbits treated with curcumin showed 1<sup>st</sup> grade cataracts, while rabbits treated with Vitamin E showed 2<sup>nd</sup> grade, and those in control groups showed 3<sup>rd</sup> grade cataracts. These findings directly showed the anti-



cataract effects of curcumin. Given to the edible route of curcumin and its beneficial effects, the synthesis of an edible drug based on curcumin for treating eye cataracts has been recommended.

## ACKNOWLEDGMENTS

Not applicable.

## REFERENCES

- Al-Musawi, AT 2022, Inhibitory activity of curcumin extract against some bacteria causing food poisoning isolated from some ready-to-eat meals. *Caspian Journal of Environmental Sciences*, 20: 1047-1052.
- Awasthi, S, Srivatava, SK, Piper, JT, Singhal, SS, Chaubey, M & Awasthi, YC 1996, Curcumin protects against 4-hydroxy-2-trans-nonenal-induced cataract formation in rat lenses. *The American Journal of Clinical Nutrition*, 64: 761–766.
- Awasthi, S, Srivatava, SK, Piper, JT, Singhal, SS, Chaubey, M & Awasthi, YC 1996, Curcumin protects against 4-hydroxy-2-trans-nonenal–induced cataract formation in rat lenses. *The American Journal of Clinical Nutrition*, 64: 761-6.
- Badaro, E, Cassini, P, Andrade, GC, Rodrigues, GB, Novais, EA & Rodrigues, EB 2022, Preliminary study of rabbits as an animal model of mammalian eye transplantation and literature review. *Revista Brasileira de Oftalmologia*, 81: e0026.
- Baha'a, A & Alzubaidy, AA 2014, Role of Topically-Applied Zinc Sulfate in Prevention of Sodium Selenite-Induced Cataract in Rabbits. *International Journal of Advanced Research*, 2: 1014-22.
- Del Amo, EM & Urtti, A 2015, Rabbit as an animal model for intravitreal pharmacokinetics: Clinical predictability and quality of the published data. *Experimental Eye Research*, 137: 111-24.
- Fichtner, JE, Patnaik, J, Christopher, KL & Petrash, JM 2021, Cataract inhibitors: Present needs and future challenges. *Chemico-Biological Interactions*, 349: 109679.
- Grama, CN, Suryanarayana, P, Patil, MA, Raghu, G, Balakrishna, N, Ravi Kumar, MNV & Reddy, GB 2013, Efficacy of biodegradable curcumin nanoparticles in delaying cataract in diabetic rat model. *PLoS ONE*, 8: e78217
- Hewlings, SJ & Kalman, DS 2017, Curcumin: A review of its effects on human health. *Foods*, 6: 92.
- Kulbay, M, Wu, KY, Nirwal, GK, Bélanger, P & Tran, SD 2024, Oxidative Stress and Cataract Formation: Evaluating the Efficacy of Antioxidant Therapies. *Biomolecules*, 14: 1055.
- Lam, D, Rao, SK, Ratra, V, Liu, Y, Mitchell, P, King, J, Tassignon, MJ, Jonas, J, Pang, CP & Chang, DF 2015, Cataract. *Nature Reviews Disease Primers*, 1: 1-5.
- López-Malo, D, Villarán-Casares, CA, Alarcón-Jiménez, J, Miranda, M, Díaz-Llopis, M, Romero, FJ & Villar, VM 2020, Curcumin as a therapeutic option in retinal diseases. *Antioxidants*, 9: 48.
- Manikandan, R, Thiagarajan, R, Beulaja, S, Chindhu, S, Mariammal, K, Sudhandiran, G & Arumugam, M 2009, Anti-cataractogenic effect of curcumin and aminoguanidine against selenium-induced oxidative stress in the eye lens of Wistar rat pups: an in vitro study using isolated lens. *Chemico-Biological Interactions*, 181: 202–209.
- Manikandan, R, Thiagarajan, R, Beulaja, S, Sudhandiran, G & Arumugam, M 2010, Curcumin prevents free radical-mediated cataractogenesis through modulations in lens calcium. *Free Radical Biology and Medicine*, 48: 483–492.
- Mapara, M, Thomas, BS & Bhat, KM 2012, Rabbit as an animal model for experimental research. *Dental Research Journal*, 9: 111.
- Meacock, WR, Spalton, DJ, Boyce, J & Marshall, J 2003, The effect of posterior capsule opacification on visual function. *Investigative Ophthalmology & Visual Science*, 44: 4665-9.
- Nunes, YC, Mendes, NM, Pereira de Lima, E, Chehadi, AC, Lamas, CB, Haber, JF, dos Santos Bueno, M, Araújo, AC, Catharin, VC, Detregiachi, CR & Laurindo, LF 2024, Curcumin: A golden approach to healthy aging: A systematic review of the evidence. *Nutrients*, 16: 2721.
- Okhovatfard, M & Rezazadeh, H 2023, Effect of Curcuma longa and its derivatives, curcumin and curcuminoids on treatment of oral lichen planus: A systematic review of clinical evidence. *Caspian Journal of Environmental Sciences*, 1-12.

- Padmaja, S & Raju, TN 2004, Antioxidant effect of curcumin in selenium induced cataract of Wistar rats. *Indian Journal of Experimental Biology*, 42: 601–603.
- Radha, A, Rukhmini, SD, Vilasini, S, Sakunthala, PR, Sreedharan, B, Velayudhan, MP & Abraham, A 2012, Bioactive derivatives of curcumin attenuate cataract formation in vitro. *Chemical Biology and Drug Design*, 80: 887–892.
- Rathore, S, Mukim, M, Sharma, P, Devi, S, Nagar, JC & Khalid, M 2020, Curcumin: A review for health benefits. *International Journal of Research and Review*, 7: 273-90.
- Shahreza, MS 2022, Ready to eat food samples as reservoirs of Shiga toxigenic *Escherichia Coli*. *Journal of Pharmaceutical Negative Results*, 31: 9761-6.
- Shahreza, MS, Dehkordi, NG, Nassar, MF & Al-Saedi, RM 2022, Virulence characters and oligotyping of *Pseudomonas aeruginosa* isolated from meat and assessment of the antimicrobial effects of *Zataria multiflora* against isolates. *Academic Journal of Health Sciences*, 37: 11-16.
- Singh, S, Sharma, S & Basu, S 2021, Rabbit models of dry eye disease: Current understanding and unmet needs for translational research. *Experimental Eye Research*, 206: 108538.
- Suryanarayana, P, Saraswat, M, Mrudula, T, Krishna, TP, Krishnaswamy K & Reddy GB 2005, Curcumin and turmeric delay streptozotocin-induced diabetic cataract in rats. *Investigative Ophthalmology & Visual Science*, 46: 2092–2099.
- Wu, S, Tong, N, Pan, L, Jiang, X, Li, Y, Guo, M & Li, H 2018, Retrospective analyses of potential risk factors for posterior capsule opacification after cataract surgery. *Journal of Ophthalmology*, 1: 9089285.
- Zernii, EY, Baksheeva, VE, Iomdina, EN, Averina, OA, Permyakov, SE, Philippov, PP, Zamyatin, AA & Senin, II 2016, Rabbit models of ocular diseases: new relevance for classical approaches. *CNS & Neurological Disorders-Drug Targets (Formerly Current Drug Targets-CNS & Neurological Disorders)*, 15: 267-91.
- Zhuang, GB, Li, X, Wu, SN, Zhang, SQ, Zhang, ZJ & Dong, N 2024, The impact of vitamin E, vitamin B6, and niacin intake on cataract incidence based on NHANES 2005-2008 data. *Frontiers in Nutrition*, 11: 1406147.