

Effects of the methanolic extract of citrus limon peeling on the liver enzymes alterations in rats due to the CPF toxicity

Sohiba Z. Khakimova^{1*}, Norpilot B. Nurov², Uktam Temirov³, Laziz T. Yuldoshov⁴, Dilbar Urazbaeva⁵, Elbek B. Jalolov⁶, Firangiz S. Ikramova⁷, K. J. Matmurotov⁸, Dildora Mavlyanova⁹, Pulat kizi S. Shavkatova¹⁰, Maxfuza Bekchanova¹¹, Ma'mura N. Khushnazarova¹², Shoxista X. Yusupova¹³

1. Professor, Head of the Department of Neurology, Faculty of Postgraduate Education, Samarkand State Medical University, Uzbekistan

2. PhD, Senior Lecturer, Department of Orthopedics and Dentistry, Bukhara State Medical Institute, Bukhara, Uzbekistan

3. Doctor of Technical Sciences, Head of the Department of Agronomy, Navoi State University of Mining and Technologies, Navoiy, Uzbekistan

4. Associate Professor, Head of the Department of Biotechnology and Food Safety, Bukhara State University, Bukhara, Uzbekistan

5. Department of Psychology and Medicine, Mamun University, Khiva Uzbekistan

6. Lecturer, Department of Biotechnology and Food Safety, Bukhara State University, Bukhara, Uzbekistan,

7. PhD Department of Otorhinolaryngology, Bukhara State Medical Institute, Bukhara, Uzbekistan

8. Dotsent, Department of "General and pediatric surgery", Tashkent Medical Academy, Tashkent, Uzbekistan

9. Department of Ecology and Water Resources Management, "Tashkent Institute of Irrigation and Agricultural Mechanization Engineers" National Research University, Tashkent, Uzbekistan

10. Master of the Department of Practical Psychology, Tashkent State Pedagogical University named after Nizami, Tashkent, Uzbekistan

11. Kimyo International University in Tashkent Shota Rustaveli Street 156, 100121, Tashkent, Uzbekistan

12. Associate Professor, Doctor of Philosophy (PhD) in Pedagogical Sciences, Kokand State University, Kokand, Uzbekistan

13. Teacher, Pharmaceuticals and Chemistry, Faculty of Medicine, Alfraganus University, Tashkent, Uzbekistan

** Corresponding author's E-mail: hakimovasohiba@list.ru*

ABSTRACT

This study evaluates the effects of the methanolic extract of citrus limon peeling on liver enzyme alterations in rats exposed to chlorpyrifos (CPF), a widely used organophosphate insecticide. Chlorpyrifos is known for its detrimental effects on non-target organisms and poses significant health risks due to its persistence in the environment and accumulation in the food chain. The research involved fifteen female Wistar rats, which were divided into three groups: a model group receiving CPF, a control group receiving phosphate-buffered saline (PBS), and a treatment group receiving both CPF and the lemon extract. The study aimed to assess the hepatoprotective properties of the lemon peel extract, which has been previously shown to mitigate liver damage caused by various toxins. The experimental design included administering CPF intraperitoneally for four weeks, followed by oral treatment with the lemon extract. Blood samples were collected to measure serum liver enzymes, specifically serum glutamic-oxaloacetic transaminase (SGOT), serum glutamic-pyruvic transaminase (SGPT), and alkaline phosphatase (ALP), which are indicators of liver function. Results indicated that the administration of the methanolic extract of citrus limon significantly reduced the elevated levels of serum SGOT, SGPT, and ALP in the CPF-treated rats, suggesting a protective effect against liver damage. Histopathological evaluations further supported these findings, demonstrating improvements in liver tissue integrity in the treatment group compared to the model group. This study highlights the potential of limon peel extract as a natural

hepatoprotective agent, offering a promising alternative for mitigating the toxic effects of organophosphate pesticides in agricultural practices.

Keywords: Antioxidant, Chlorpyrifos, Liver, Limon peel extract.

Article type: Research Article.

INTRODUCTION

Pesticides play a crucial role in agricultural methodologies and public health strategies, as they are utilized to control agricultural pests, reduce food loss, and manage organisms that transmit diseases, thereby safeguarding the health of both humans and animals. The ongoing growth of the global population has intensified the demand for improved food production, leading to a greater dependence on the application of pesticides (Blain 2011; Taghavian *et al.* 2016). Organophosphate pesticides (OPs), derived from phosphorus-based compounds such as phosphoric and phosphorothioic acids, are among the most commonly used pesticides globally. Each year, approximately 2 million tons of pesticides are utilized worldwide, with projections indicating an increase to 3.5 million tons by 2020, of which nearly 40% are expected to be OPs. Although OPs have been in use for pest control for over fifty years, their application has intensified following the ban on organochlorine pesticides. This rise in usage can be attributed to the relatively short environmental lifespan of OPs and their lower health risks compared to organochlorine pesticides. However, improper practices related to the use, storage, transport, application, and disposal of pesticide residues present significant risks to non-target species. OPs can enter living organisms through three main exposure pathways: ingestion, inhalation, and dermal contact (Mansukhani *et al.* 2024). Chlorpyrifos, known scientifically as O, O-diethyl O-3,5,6-trichloro-2-pyridyl phosphorothioate, appears as white or colorless crystalline solids. This chemical is utilized in the control of a range of pests, including termites, mosquitoes, and nematodes. Since its authorized use in 1965, it has been allowed in both agricultural and non-agricultural settings (Nandi *et al.* 2022). As a result, chlorpyrifos is frequently found in environmental samples, which raises considerable public health issues. In Iran, the use of chlorpyrifos (CPF) in agricultural activities is widespread; however, the presence of its residues on crops presents substantial health hazards to humans, as demonstrated by a multitude of scholarly research. CPF has been detected in diverse environmental settings, including surface waters, seawater, and rainfall (Kermani *et al.* 2021). Current therapeutic approaches exhibit limited success in halting or preventing the symptomatic advancement of degenerative diseases, primarily concentrating on symptom alleviation rather than tackling the underlying pathologies. This scenario highlights the urgent necessity for the development of alternative pharmacological agents aimed at preventing and safeguarding against these age-related disorders (Lips 2006). Citrus fruits, belonging to the Rutaceae family, are recognized for their significant medicinal properties. Citrus plants, which besides lemons also count, for example, limes, oranges, kumquats, mandarins and grapefruits, each with numerous varieties, all belong to the genus “Citrus” and the Rutaceae family. Botanically speaking, they are berries. Their cultivation follows a very specific plan. They are primarily valued for their alkaloids, which exhibit anticancer effects and possess antibacterial capabilities in crude extracts derived from various parts of the lemon, including leaves, stems, roots, juice, peels, and flowers, against a range of bacterial strains. The biological activities of citrus fruits are extensive, encompassing antibacterial, antifungal, antidiabetic, anticancer, and antiviral properties attributed to their alkaloid content (Zia-ur-Rehman 2006; Ali *et al.* 2017). Extraction of lemon peel is typically performed using various solvents such as ethanol, methanol, and acetone, followed by antibacterial assays. Notably, methanolic extracts demonstrate superior antimicrobial efficacy against tested pathogens. Citrus peels are abundant in nutrients and host a variety of phytochemicals, including β and γ -sitosterol, glycosides, and volatile oils. Additionally, they contain unique polyethoxylated phenolic compounds, ascorbic acid, and flavonoids, which exhibit significant biological activities that are uncommon in other plant species. Traditionally, citrus peels have been utilized for treating conditions such as scurvy, digestive issues, respiratory ailments, peptic ulcers, eye infections, gum diseases, gout, skin care, hemorrhoids, urinary disorders, and weight management (Zia-ur-Rehman 2006). Furthermore, they serve as disinfectants and sterilizing agents. The application of pesticides has markedly enhanced product quality. Nonetheless, the potential impacts on various essential organs remain largely uncharted, prompting researchers to explore and assess these adverse effects. Consequently, this study aimed to examine the possible effects and underlying mechanisms of chlorpyrifos (CPF) exposure on the liver. Researchers are investigating innovative therapeutic approaches, particularly in developed countries, to improve the quality of life

for patients suffering from lung diseases attributed to the inhalation or ingestion of toxins. Consequently, the current study sought to evaluate the therapeutic impact of lemon peels extract on organ alterations induced by CPF poisoning in rats, to identify potential adjunctive treatments following such poisoning events.

MATERIALS AND METHODS

Preparation of *Citrus limon* peel extracts

Citrus limon specimens were procured from the national market. The peels of *C. limon* were shade-dried and subsequently ground into a powder using an electric blender. The powdered material was defatted with ether, after which the residue was dried and extracted with chloroform. Following another drying phase, the residue was finally extracted with methanol utilizing a Soxhlet extractor. The percentage yield of the methanolic extract was subsequently calculated.

Preparation of extract/stock solution

A stock solution of the *C. limon* peel extract was prepared on each occasion by accurately weighing the extract and dissolving it in an appropriate volume of dimethyl sulfoxide (DMSO) to achieve a concentration of 100 mg mL⁻¹. Additionally, a ciprofloxacin tablet was dissolved in a suitable volume of water to create a stock solution with a concentration of 5 mg mL⁻¹ as mentioned in previous studies (Ali *et al.* 2017).

Experimental animals study design

Fifteen female Wistar rats, age between 6 to 8 weeks and weighing an average of 188 ± 10.2 g, were acquired for the study. The animals were maintained in a controlled environment adhering to established protocols: a room temperature of 21 ± 2 °C, a light-dark cycle of 14 L: 10 D, and a relative humidity of 50-55%. The rats were provided with sufficient water through polycarbonate bottles and were fed a diet consisting of commercial rodent pellets. All procedures involving the animals were conducted following the guidelines for the care and use of laboratory animals as outlined in NIH Publications No. 8023, revised in 1978, and complied with the ethical standards set forth by the Institutional Animal Care and Use Committee.

The selected rats were divided randomly into the following three groups (n = 5 / group):

Group 1: CPF (Model group) received CPF without treatment; (3 mg kg⁻¹ for 4 weeks; Intraperitoneally; Gheibi *et al.* 2020, 2023).

Group 2: Control group in which healthy rats received phosphate buffered saline (PBS; for 28 days; Gavage).

Group 3: CPF + Treatment (Treatment group). After induction, the model with CPF (3 mg kg⁻¹ for 4 weeks; Intraperitoneally), plant extracts were prepared in DMSO (stock: 1 mg mL⁻¹ DMSO; 200 µL) prescribed orally, 28 days (Amanpour *et al.* 2024; Sharifnia *et al.* 2024).

The appropriate doses of CPF and extract were obtained from previous studies (Barzi *et al.* 2020; Vahabi Barzi *et al.* 2022). At the end of the experiment, rats were euthanized in a CO₂ +O₂ chamber. Blood samples were taken by cardiac puncture method, and the sera were separated by centrifugation (Hettich-Germany) at 4000 rpm, 10 min, and refrigerated at -20 °C.

Measurement of oxidative stress biomarkers

The concentration of serum total oxidant status (TOS) was assessed utilizing an automated colorimetric technique as described by Erel (2004). The first reagent comprised 150 µM xylenol orange, 140 mM sodium chloride, and 1.35 M glycerol dissolved in 25 mM sulfuric acid at a pH of 1.75. The second reagent included 5 mM Fe³⁺ and 5 mM 4-(4-amino-3-methoxyphenyl)-2-methoxyaniline in 25 mM sulfuric acid. Absorbance measurements were taken at 650 nm after a 3-minute incubation period, using a blank for reference. To derive the TOS values, a standard curve was initially established, followed by the application of the regression equation $y = mx \pm b$. The total antioxidant capacity (TAC) of the serum samples was evaluated through a spectrophotometric method also developed by Erel (2004). The first reagent for this assay contained 5 mM Fe³⁺ and 10 mM 4-(4-amino-3-methoxyphenyl)-2-methoxyaniline in a Clark and Lubs solution at a concentration of 75 mM and a pH of 1.8. The second reagent was composed of 7.5 mM hydrogen peroxide in the same Clark and Lubs solution. Absorbance readings were taken at 440 nm after 3 minutes, again using a blank for calibration. The TAC values were calculated following the establishment of a standard curve and the use of the regression equation $y = mx \pm b$ (Abod *et al.* 2021).

Evaluation of liver biomarkers

Following heart puncture to acquire blood samples, the concentrations of serum glutamic-oxaloacetic transaminase (SGOT), serum glutamic-pyruvic transaminase (SGPT), and alkaline phosphatase (ALP) were measured spectroscopically using commercial kits (Amanpour *et al.* 2024).

Histopathological evaluation of the kidney

At the experiment's conclusion, the animals were euthanized through the administration of an overdose of xylazine and ketamine, and the organs were isolated. The obtained kidney samples from rats were fixed in a 10% formalin solution for tissue processing. The fixed samples were embedded in paraffin, and serial paraffin sections (with a thickness of 4-6 μm) were prepared for hematoxylin and eosin staining (Jabbari *et al.* 2020).

Statistical analysis

Data were reported as mean \pm SD, and the graphs were plotted using Graph Pad Prism 5.04 software. Data were statistically analyzed using analysis of variances (ANOVA) followed by a post-Tukey test, and a p -value less than 0.05 was considered a significant difference to compare the model group that received CPF without treatment. The asterisks replicate significant differences with *: $p < 0.05$, **: $p < 0.01$, and ***: $p < 0.001$.

RESULTS

Serum total oxidant status (TOS) and total antioxidant capacity (TAC)

Fig. 1A shows that the TAC concentration in the treatment group was significantly lower than in the CPF group ($p < 0.0001$). The TAC concentration in the prescribed extract group showed a significant difference compared to the control group ($p < 0.0001$). The data in Fig. 1B indicate a significant increase in TOS concentration in the treatment group with extract compared to the CPF group ($p < 0.0001$). Additionally, rats exposed to treatment displayed significant differences from the control group ($p < 0.0001$).

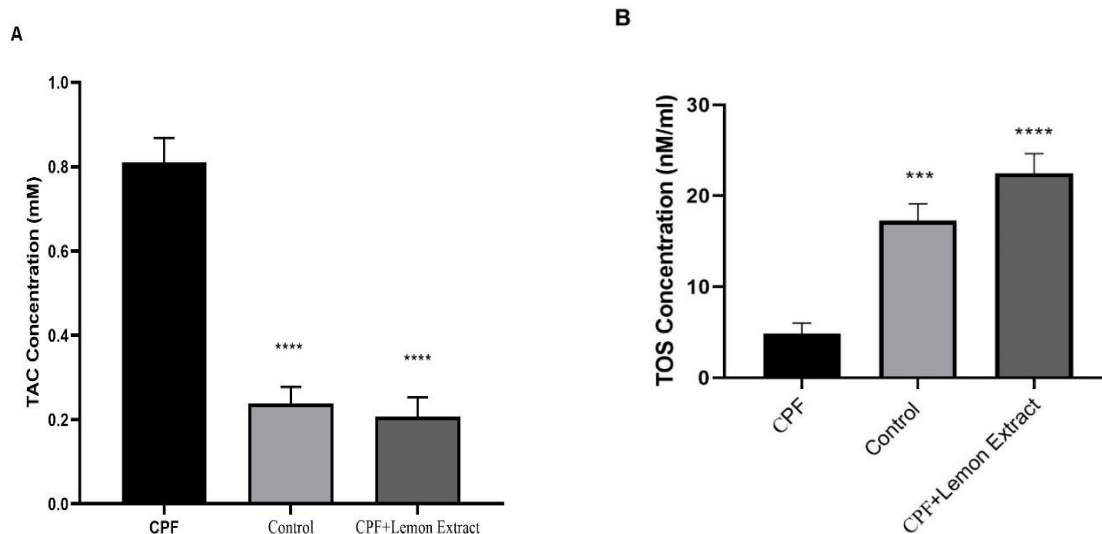


Fig. 1A: TAC activity in sera samples isolated from CPF, Control, and CPF + limon Extract. **Fig. 1B:** TOS activity in sera samples isolated from CPF, Control, and CPF + limon Extract. Data were statistically analyzed using analysis of variances (ANOVA) followed by a post-Tukey test, and a p -value less than 0.05 was considered a significant difference to compare the model group that received CPF without treatment. The asterisks replicate significant differences with *: $p < 0.05$, **: $p < 0.01$, and ***: $p < 0.001$.

Liver enzyme levels

Oral prescription of lemon peel extract significantly diminished the serum SGOT level compared to that in the CPF group ($p < 0.01$). The serum SGPT of rat in the treatment group was significantly lower than those in the CPF group ($p < 0.05$). Treatment with extract had an overall lessening effect on the ALP concentration compared to that in the CPF group ($p < 0.01$).

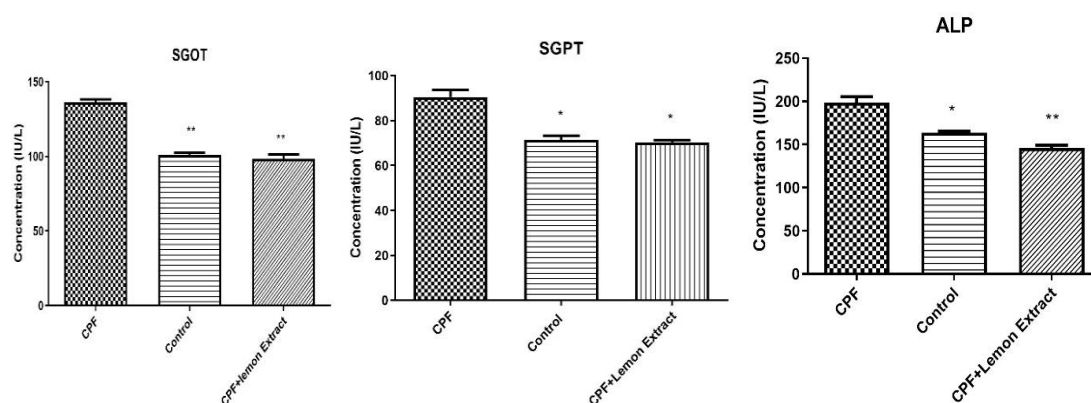


Fig .2. The effects of CPF administration and treatment with limon extract on the serum level of SGOT, SGPT, and ALP of rat in experimental groups. Data are represented as Mean \pm SD. One-Way ANOVA followed by a post hoc LSD test was used for comparison between different groups. The asterisks replicate significant differences with *: $p < 0.05$, **: $p < 0.01$, and ***: $p < 0.001$.

Histopathological evaluation of the liver

Liver tissue sections stained with hematoxylin and eosin (H & E) were examined to assess the histopathological effects of chlorpyrifos (CPF) and the potential protective role of lemon extract (Fig. 3). In the Control group, the liver architecture appeared normal with proper sinusoidal, and without inflammatory infiltration. In contrast, the CPF-treated group exhibited marked histopathological alterations, including hepatocellular degeneration, cytoplasmic vacuolation, dilated sinusoids, and dense inflammatory cell infiltration around the central vein. These changes are indicative of significant liver injury associated with CPF exposure. Interestingly, co-administration of lemon extract in the CPF + Lemon Extract group led to a considerable improvement in liver architecture. Hepatocytes appeared more regularly arranged, central veins were preserved, and signs of inflammation and degeneration were markedly reduced compared to the CPF group. These observations suggest that lemon extract exerts a protective effect against CPF-induced hepatic damage.

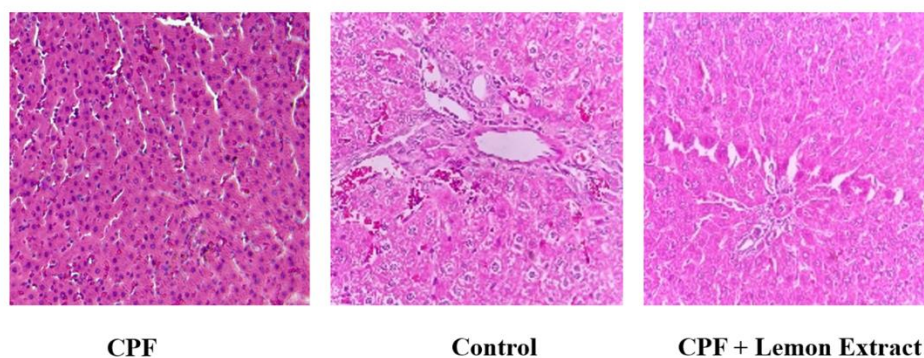


Fig. 3. Histopathological evaluation of three various groups (Control, Model, and Model received lemon extract). Histopathological examination of liver tissues stained with hematoxylin and eosin (H & E; magnification: $\times 400$). Control group: Liver tissue shows normal texture and sinusoids. CPF group: Marked hepatocellular degeneration, cytoplasmic vacuolation, sinusoidal dilation, and inflammatory cell infiltration are evident, indicating significant liver damage due to chlorpyrifos exposure. CPF + Lemon Extract group: Liver architecture is notably improved, with more regular hepatocyte arrangement and reduced signs of degeneration and inflammation, suggesting a hepatoprotective effect of lemon extract.

DISCUSSION

This research represents the inaugural experimental investigation into the impact of lemon peel extract supplementation on CPF toxicity in rats subjected to CPF exposure. The findings indicate that supplementation with lemon peel extract may alleviate liver damage caused by CPF by modulating inflammatory responses and biomarkers, in addition to enhancing antioxidant levels. The methanolic extract of lemon peeling has garnered significant attention in recent years due to its potential health benefits and industrial applications. Lemons serve

as significant sources of phytochemicals, with their peels being particularly abundant in flavonoids, which are powerful antioxidants recognized for their health advantages. Flavonoids such as hesperidin and naringin, present in lemon peel, have been linked to a variety of health-enhancing effects. These compounds demonstrate anti-inflammatory and antioxidant properties that may contribute to a decreased risk of chronic illnesses, including cardiovascular disease and cancer. Moreover, they have shown promise in enhancing cardiovascular health by improving vascular function and reducing blood pressure. Additionally, the flavonoids found in lemon peel may aid digestive health by stimulating the secretion of digestive enzymes and enhancing gut motility. Incorporating lemon peel into the diet—whether through grating, zesting, or adding to various dishes—provides a flavorful and nutritious means of accessing the beneficial phytochemicals inherent in this citrus fruit, thereby promoting overall health and wellness. Antioxidants, which are frequently natural substances obtained from plants or artificially produced, can counteract Reactive Oxygen Species (ROS) and free radicals that arise during oxidative stress. Through the donation of electrons or hydrogen atoms, antioxidants can successfully stabilize these highly reactive entities, thereby averting potential cellular harm. Chlorpyrifos, an extensively used organophosphate insecticide, is integral to pest control in agricultural systems worldwide. However, its frequent and indiscriminate use in crop production can have detrimental effects on non-target organisms, such as both aquatic and terrestrial wildlife, by leading to the contamination of water sources. This contamination raises potential health concerns for humans via the food chain. A multitude of studies has reported increased residual levels of chlorpyrifos in water, soil, and a range of agricultural products, including fruits and vegetables, in various countries (Gheibi *et al.* 2020). The antioxidant properties of lemon peel extracts are a key mechanism underlying their hepatoprotective effects. Lemon peels are rich in bioactive compounds such as flavonoids, limonoids, and ascorbic acid, which contribute to their antioxidant activity. These compounds help mitigate oxidative stress by scavenging free radicals and enhancing the body's antioxidant defense system. Studies have shown that methanolic extracts of citrus peels can reduce lipid peroxidation and increase the levels of endogenous antioxidants such as glutathione (GSH), superoxide dismutase (SOD), and glutathione peroxidase (GPx) in the liver (Mohamed *et al.* 2014; Miler *et al.* 2024). The extract has been found to upregulate the expression of nuclear factor erythroid 2-related factor 2 (Nrf2), a transcription factor that regulates the expression of antioxidant genes. This upregulation enhances the liver's ability to combat oxidative damage (Miler *et al.* 2024; Setudeh & Arabi 2024). Methanolic extracts of citrus peels have been shown to mitigate paracetamol-induced liver damage by reducing the levels of serum liver enzymes such as alanine aminotransferase (ALT) and aspartate aminotransferase (AST). These effects are comparable to those of standard hepatoprotective drugs like silymarin (Asjad *et al.* 2023; Charmkar *et al.* 2024). In a study on Wistar rats, the methanolic extract of citrus sinensis peel exhibited significant hepatoprotection against isoniazid and rifampicin-induced liver injury. The extract reduced ALT and AST levels and improved histopathological liver changes (Kosasih *et al.* 2019). In agreement with previous studies, in the present study, following the prescription of lemon extract in CPF received rats, the liver enzymes declined in the lemon extract group. A study on cadmium-exposed rats demonstrated that the methanolic extract of lemon pepper fruit peel significantly reduced liver damage markers such as ALT and AST. The highest dose of the extract (1,200 mg kg⁻¹) showed the most pronounced protective effect, decreasing ALT by 41.10% and AST by 59.39% compared to the control group (Kosasih *et al.* 2019). Citrus peel extracts have been found to ameliorate high-fat diet-induced NAFLD by activating AMP-activated protein kinase (AMPK) signaling. This activation helps regulate lipid metabolism and reduce hepatic steatosis. In aged rats, lemon extract supplementation reduced hepatic oxidative stress and persulfidation levels by upregulating Nrf2 and thioredoxin 1 (Trx1) expression. These findings suggest the potential of lemon extracts to mitigate age-related liver dysfunction (Lee *et al.* 2020; Miler *et al.* 2024). In addition to their antioxidant and hepatoprotective effects, methanolic lemon peel extracts have been investigated for their anti-inflammatory and anti-carcinogenic properties. The extracts have been shown to suppress inflammatory cytokines such as tumor necrosis factor-alpha (TNF-α) and interleukin-1β (IL-1β), which are involved in liver inflammation and damage. In a study on diethylnitrosamine (DEN)/2-acetylaminofluorene (2AAF)-induced hepatocellular carcinoma (HCC), the hydroethanolic extract of lemon peel and its constituent limonene significantly attenuated tumorigenesis. The extract suppressed the expression of pro-inflammatory and pro-proliferative markers, suggesting its potential in preventing liver cancer (Al Mousawi *et al.* 2020; Ezzat *et al.* 2024). The hepatoprotective effects of methanolic lemon peel extracts are further supported by biochemical and histopathological studies. Across various studies, the extracts have been shown to reduce elevated levels of liver enzymes (ALT, AST, ALP), bilirubin, and lipid peroxidation markers such as malondialdehyde (MDA; Mohamed

et al. 2014; Charmkar *et al.* 2024). Histopathological examinations have revealed that treatment with lemon peel extracts reduces liver damage, such as ballooning degeneration, necrosis, and inflammatory cell infiltration, restoring the liver's normal architecture. The hepatoprotective effects of methanolic lemon peel extracts have been observed to be dose-dependent in several studies. In a study on cadmium-induced liver damage, the highest dose of lemon pepper methanol extract (1,200 mg kg⁻¹) exhibited the most significant protective effect, reducing ALT and AST levels by 41.10% and 59.39%, respectively. The extracts have been generally well-tolerated in animal studies, with no adverse effects reported at the tested doses. This suggests their potential safety for use in therapeutic applications (Mohamed *et al.* 2014; Tanaka *et al.* 2022). In our investigation, the application of lemon peel extract resulted in a notable reduction in serum SGOT levels when compared to the CPF group. Furthermore, the serum SGPT levels in the treatment group of rats were significantly lower than those observed in the CPF group. The administration of the extract also led to a marked decrease in ALP concentration relative to the CPF group. Additionally, there was a reduction in TAC and an increase in TOC following the oral administration of lemon extract. Histopathological analyses revealed an improvement in liver architecture that had been compromised due to CPF exposure. The methanolic extract of lemon peeling has demonstrated significant hepatoprotective effects against various liver injury models, including drug-induced hepatotoxicity, heavy metal toxicity, and metabolic disorders. These effects are primarily mediated through antioxidant, anti-inflammatory, and anti-carcinogenic mechanisms. The extract's ability to reduce oxidative stress, suppress inflammatory pathways, and restore liver function highlights its potential as a natural remedy for liver protection.

CONCLUSION

The findings of this study provide compelling evidence for the hepatoprotective effects of the methanolic extract of *Citrus limon* peeling against chlorpyrifos (CPF) toxicity in rats. The research demonstrates that supplementation with lemon peel extract can significantly alleviate liver damage induced by CPF exposure, as indicated by the reduction in serum liver enzyme levels, specifically serum glutamic-oxaloacetic transaminase (SGOT), serum glutamic-pyruvic transaminase (SGPT), and alkaline phosphatase (ALP). The study highlights the role of bioactive compounds present in lemon peel, such as flavonoids, which possess potent antioxidant and anti-inflammatory properties. In addition to the biochemical improvements, histopathological evaluations revealed that the liver tissue integrity was significantly better in the treatment group compared to the model group, further supporting the protective effects of the lemon peel extract. Overall, this study underscores the potential of *C. limon* peel extract as a natural therapeutic agent for mitigating the adverse effects of organophosphate pesticides like chlorpyrifos. The incorporation of lemon peel into dietary practices may offer a simple and effective strategy to promote liver health and reduce the risks associated with pesticide exposure, thereby contributing to public health and safety in agricultural contexts.

REFERENCES

- Abod, KS, Mohammed, MT & Taay, YM 2021, Evaluation of total oxidant status and antioxidant capacity in sera of acute-and chronic-renal failure patients. *Journal of Physics: Conference Series*, IOP Publishing, 12038.
- Ali, J, Das, B & Saikia, T 2017, Antimicrobial activity of lemon peel (*Citrus limon*) extract. *International Journal of Current Pharmaceutical Research*, 9: 79-82.
- Al Mousawi, AH, Chessab, RM. and Alquraishy, MK, 2022, Inhibition of biofilm formation by Methicillin-resistant *Staphylococcus warneri* using *Citrus limon* oil. *Caspian Journal of Environmental Sciences*, 20: 197-201.
- Amanpour, P, Eftekhari, Z, Eidi, A & Khodarahmi, P 2024, Ameliorative mechanism of dietary vitamin D and magnesium on newborn's pulmonary toxicity induced by cadmium. *Journal of Trace Elements in Medicine and Biology: Organ of the Society for Minerals and Trace Elements (GMS)*, 84: 127469.
- Asjad, HMM, Akhtar, MS, Khan, M, Sial, NT, Sohail, I & Arshad, L 2023, Ethanolic extract of *Citrus sinensis* peel markedly mitigate paracetamol-induced hepatotoxicity in rats. *Journal of Health and Rehabilitation Research*, 3: 1058-1062.
- Barzi, NV, Eftekhari, Z, Doroud, D & Eidi, A 2020, DNA methylation changes of apoptotic genes in organogenesis stage of mice embryos by maternal chlorpyrifos induction. *Environmental toxicology*, 35: 794–803.
- Blain, PG 2011, Organophosphorus poisoning (acute). *BMJ Clinical Evidence*, England.

- Charmkar, RP, Dubey, N & Ganeshpurkar, A 2024, Evaluation of Lemon Peel Extract as Hepatoprotective Agent against Paracetamol-Induced Liver Toxicity: Insights from Biochemical Studies. *Free Radicals and Antioxidants*, 4: 15-20.
- Erl, O 2004, A novel automated direct measurement method for total antioxidant capacity using a new generation, more stable ABTS radical cation. *Clinical Biochemistry*, 37: 277-285. DOI: 10.1016/j.clinbiochem.2003.11.015.
- Ezzat, RS, Abdel-Moneim, A, Zoheir, KMA, Mohamed, EE, Abou-Seif, HS, Hefnawy, M & Ahmed, OM 2024, Anti-carcinogenic effects and mechanisms of actions of Citrus limon fruit peel hydroethanolic extract and limonene in diethylnitrosamine/2-acetylaminofluorene-induced hepatocellular carcinoma in Wistar rats. *American Journal of Cancer Research*, 14: 5193.
- Gheibi, P, Eftekhari, Z, Doroud, D & Parivar, K 2023, Association between uterine toxicity induced by chlorpyrifos and downregulation of heparin-binding epidermal growth factor and L-selectin genes. *Veterinary Research Forum: an International Quarterly Journal*, 14: 45-52.
- Gheibi, P, Eftekhari, Z, Doroud, D & Parivar, K 2020, Chlorpyrifos effects on integrin alpha v and beta 3 in implantation window phase. *Environmental Science and Pollution Research*, 27: 29530–29538.
- Jabbari, N, Eftekhari, Z, Roodbari, NH & Parivar, K 2020, Evaluation of encapsulated eugenol by Chitosan nanoparticles on the aggressive model of rheumatoid arthritis. *International Immunopharmacology*, 85: 106554.
- Kermani, M, Dowlati, M, Gholami, M, Sobhi, HR, Azari, A, Esrafil, A, Yeganeh, M & Ghaffari, HR 2021, A global systematic review, meta-analysis and health risk assessment on the quantity of Malathion, Diazinon and Chlorpyrifos in Vegetables. *Chemosphere*, 270: 129382.
- Kosasih, E, Chiuman, L, Lister, INE & Fachrial, E 2019, Hepatoprotective effect of citrus sinensis peel extract against isoniazid and rifampicin-induced liver injury in wistar rats. *Majalah Obat Tradisional*, 24:197-203.
- Lee, G-H, Peng, C, Park, S-A, Lee, H-Y, Kim, J, Kang, S-I, Lee, C-H, Lee, J-S & Chae, H-J 2020, Citrus peel extract ameliorates high-fat diet-induced NAFLD via activation of AMPK signaling. *Nutrients*, 12: 673.
- Lips, P 2006, Vitamin D physiology. *Progress in Biophysics and Molecular Biology*, 92: 4-8.
- Mansukhani, M, Roy, P, Ganguli, N, Majumdar, S & Sharma, S 2024, Organophosphate pesticide chlorpyrifos and its metabolite 3,5,6-trichloropyridinol downregulate the expression of genes essential for spermatogenesis in caprine testes. *Pesticide Biochemistry and Physiology*, 204: 106065.
- Miler, M, Živanović, J, Ajdžanović, V, Milenkovic, D, Cesar, T, Filipović, MR & Milošević, V 2024, Lemon extract reduces the hepatic oxidative stress and persulfidation levels by upregulating the Nrf2 and Trx1 expression in old rats. *Biofactors*, 50: 756-771.
- Mohamed, NAE, Tohamy, AA & Elgamal, B 2014, Ameliorative effect of citrus peel extract on castration-induced oxidative stress in liver and kidney of rats. *Journal of Applied Pharmaceutical Science*, 4: 64–68.
- Nandi, NK, Vyas, A, Akhtar, MJ & Kumar, B 2022, The growing concern of chlorpyrifos exposures on human and environmental health. *Pesticide biochemistry and physiology*, 185: 105138.
- Sharifnia, M, Eftekhari, Z & Mortazavi, P 2024, Niosomal hesperidin attenuates the M1/M2-macrophage polarization-based hepatotoxicity followed chlorpyrifos-induced toxicities in mice. *Pesticide Biochemistry and Physiology*, 198: 105724.
- Setudeh, F. and Arabi, M, 2024, Oxidative stress biomarkers in hepatic and cardiac toxicity induced by copper oxide nanoparticles in mice. *Journal of Chemical Health Risks*, 14(4).
- Tanaka, S, Ginting, CN, Chiuman, L & Nasution, AN 2022, Lemon pepper's kidney protection effect against kidney injury induced by Cadmium in male Wistar Rats. *IOP Conference Series: Earth and Environmental Science*, 12031.
- Taghavian, F, Vaezi, G, Abdollahi, M & Malekiran, AA, 2016, A comparative study of the quality of life, depression, anxiety and stress in farmers exposed to organophosphate pesticides with those in a control group. *Journal of Chemical Health Risks*, 6(2).
- Vahabi Barzi, N, Eftekhari, Z, Doroud, D & Eidi, A 2022, Maternal exposure during organogenesis to chlorpyrifos insecticide induces the apoptosis process. *The Journal of Maternal-Fetal & Neonatal Medicine: The Official Journal of the European Association of Perinatal Medicine, the Federation of Asia and Oceania Perinatal Societies, the International Society of Perinatal Obstetricians*, 35: 3845–3852.
- Zia-ur-Rehman 2006, Citrus peel extract – A natural source of antioxidant. *Food Chemistry*, 99: 450–454.