

Evaluation of male rats' genital system alterations caused by cadmium with consumption of total methanolic extract of orange peel

Gulnihol I. Sharipova^{1*}, Muxabbat Arsenova², Abdumalik Rizayev³, Odilbek uglu V. Sapayev⁴, Durdona Azimova⁵, Farrukh Akchayev⁶, Gairat U. Lutfullaev⁷, Feruza Sh. Tukhtaeva⁸, Abdugani Suyunov⁹, Gulomidin M. Khodzhimatov¹⁰

¹ Associate Professor of the Department of Hygiene No.2 of the Bukhara State Medical Institute named after Abu Ali Ibn Sino, Uzbekistan

² Kimyo International University in Tashkent Shota Rustaveli Street 156, 100121, Tashkent, Uzbekistan

³ Professor, Doctor of Technical Sciences, Tashkent State Transport University, Tashkent, Uzbekistan

⁴ Department of General Professional Science, Mamun University, Khiva, Uzbekistan

⁵ Assistant Professor, Navoi State University of Mining and Technologies, Navoi, Uzbekistan

⁶ Associate Professor, Jizzakh State Pedagogical University, Jizzakh, Uzbekistan

⁷ Doctor of Medical Sciences, Professor, Head of the Department of Otorhinolaryngology FPDO. Samarkand State Medical University, Samarkand, Uzbekistan

⁸ Pharmaceuticals and Chemistry, Faculty of Medicine, Alfraganus University, Tashkent, Uzbekistan

⁹ Head of the Department of Hydraulic Installations and Pumping Stations, Karshi State Technical University, Kashkadarya, Uzbekistan

¹⁰ Professor of the Department of General Surgery, Anesthesiology- Reanimatology and Ophthalmology, Andijan State Medical Institute, Andijan, 170100, Uzbekistan

Corresponding Author E-mail: sharipova.gulnihol@bsmi.uz ; gulniholsharipova86@gmail.com

ABSTRACT

Cadmium (Cd) is a hazardous heavy metal devoid of any essential biological function, presenting considerable risks to both human and animal health, even at minimal exposure levels. This investigation examines the influence of cadmium on the male reproductive system of rats. It assesses the probable preserving effects of the total methanolic extract derived from orange peel, *Citrus sinensis*. The research underscores that cadmium, a common environmental contaminant from industrial processes, can accumulate in biological tissues, particularly within the testes, leading to reproductive toxicity and structural impairments. The study involved administering cadmium chloride to male rats at a concentration of 2 mg kg⁻¹, while a separate cohort received orange peel extract (250 mg kg⁻¹). The experimental period lasted eight weeks, with daily treatments delivered via gavage. The results revealed significant changes in liver enzyme levels, indicating hepatic damage and oxidative stress associated with cadmium exposure. Conversely, the administration of orange peel extract exhibited both protective and restorative effects against liver toxicity induced by cadmium, as demonstrated by a decrease in oxidative stress markers. These outcomes highlight the possibility of the orange peel as an expected intervention to alleviate the detrimental effects of cadmium toxicity in the male reproduction system. This research enhances the understanding of cadmium influence on male reproductive health and emphasizes the therapeutic advantages of natural extracts in addressing heavy metal-induced harm. Overall, the

study underscores the necessity of investigating natural products' protective capabilities against environmental toxins, thereby paving the way for future inquiries in this domain.

Keywords: Cd, Testitis, Liver, Orange peeling.

Article type: Original Article.

INTRODUCTION

Cadmium (Cd) is categorized as a xenobiotic metal due to its absence of any essential biological role, which presents significant risks to humans, animals, and plants, even at small concentrations. In natural ecosystems, Cd is identified as a heavy metal contaminant that can have harmful effects. It can accumulate and bioaccumulate in living organisms and environmental media such as water, air, and soil (Fahim *et al.* 2024). The absorption of Cd varies depending on the exposure route, with inhalation, ingestion, and dermal contact having a minimal impact on overall absorption. Cd is widely recognized as an environmental pollutant from various industrial processes, including tobacco consumption (Genchi *et al.* 2020).

Cd permeates the food web following environmental contamination. Human exposure to Cd occurs via pollutants found in the atmosphere, drinking water, and food sources. Moreover, tobacco smoking is a notable contributor to Cd exposure, with smokers displaying Cd concentrations that are 4 to 5 times higher than those found in non-smokers (Järup 2002). Testicular tissue, in particular, shows a heightened susceptibility to Cd accumulation. In studies conducted on rats, Cd levels in the testes were 100 times greater than those in the bloodstream after a 14-day exposure period. Numerous investigations have confirmed that mammalian testes are at risk from Cd exposure, which can result in male reproductive toxicity, including damage to testicular structures. The primary sources of Cd emissions are industries such as battery production, electroplating, pigment manufacturing, plastic production, and the use of fertilizers. The general populace encounters Cd through contaminated food and drinking water (Antar *et al.* 2023).

Cadmium (Cd) exposure can occur through both occupational and non-occupational pathways. Occupational hazards primarily stem from the use of cadmium in various industrial processes. In contrast, the main non-occupational sources of cadmium exposure include contaminated drinking water, tobacco smoke, and environmental air pollution (Hayat *et al.* 2019). The testis is particularly vulnerable to cadmium toxicity, as evidenced by studies led on animal models and human populations. The cadmium toxicological effects are not limited to the reproductive system; they also extend to vital organs such as the kidneys, liver, and lungs. Due to its resistance to metabolic transformation and prolonged body retention, cadmium is categorized as a highly toxic heavy metal (Eagderi *et al.* 2017). Evidence suggests that cadmium exposure can lead to mitochondrial dysfunction and increased oxidative stress, both of which are critical factors contributing to testicular toxicity (Ikokide *et al.* 2022): the heightened sensitivity of mammalian testes to cadmium results in reduced sperm motility and a lower spermatogenesis index. Furthermore, prolonged exposure to cadmium may adversely affect the chromatin structure of sperm, potentially compromising fertility. The testicular toxicity associated with cadmium exposure is primarily attributed to oxidative damage alongside these various alterations (Antar *et al.* 2023).

Cadmium exposure significantly disrupts the male reproductive system, leading to impaired spermatogenesis, heightened oxidative stress, inflammation, and hormonal imbalances. These disruptions reduce fertility and testicular damage in affected rats (Park *et al.* 2014; Ndubuisi *et al.* 2020). Studies suggest that the total methanolic extract of orange peel (TMEOP) may mitigate these adverse effects due to its antioxidant properties and capacity to neutralize free radicals, as well as its role in alleviating testicular morphological changes and promoting spermatogenesis and fertility. These findings indicate that TMEOP could be a capable natural therapeutic agent for addressing the harmful consequences of cadmium exposure on male reproductive health. Recently, there has been an increasing focus among researchers on utilizing natural remedies to counteract cadmium toxicity, mainly through the exploration of plant-derived extracts (Akinhanmi *et al.* 2020).

Citrus flavonoids, especially hesperidin, are associated with extensive therapeutic effects, such as anti-inflammatory activity (Akachukwu *et al.* 2024). The concentration of antioxidant compounds varies across different parts of the orange, leading to fluctuations in antioxidant activity among these segments. Generally, the orange peel contains a higher concentration of antioxidant compounds than the fruit's flesh (Mohamed *et al.* 2014).

Orange peels, known for their rich content of bioactive compounds, have demonstrated potential in adsorbing cadmium ions from water and alleviating cadmium-related toxicity in living organisms. This study offers a detailed examination of the efficacy of orange peel extracts in combating cadmium toxicity, emphasizing their antioxidant, chelating, and adsorption capabilities. Various previous research efforts have investigated the ability of certain substances to alleviate heavy metal toxicity, revealing their effectiveness in lowering levels of lead, cadmium, and mercury in various organs (Ekhtator *et al.* 2022). Therefore, this research examines explicitly the methanol extract of orange peels to evaluate its protective effects against cadmium toxicity in rats, as there has been no prior research addressing the impact of this extract on cadmium-induced toxicity in the male reproductive system.

MATERIALS AND METHODS

Orange peel extraction

The edible segments of the orange peels (OP) were taken, briefly washed with water, and then wholly air-dried over the course of one day before being diced into approximately 2×2 cm pieces. A total of 10 g of OP was subjected to extraction with 200 mL methanol for 72 hours at a controlled temperature of 25 °C. The resulting extracts were filtered, and the solvents used in the extraction process were removed using an evaporator (IKA, Germany). Subsequently, the extracts of OP were reconstituted in dimethyl sulfoxide (DMSO) to achieve a concentration of 50 mg mL⁻¹ and were stored at -20 °C for future applications (Park *et al.* 2014).

Cytotoxicity assay by MTT

HepG2 cells were obtained from the National Culture Collection and cultured in DMEM enriched with 10% fetal bovine serum (FBS), penicillin (100 U mL⁻¹), streptomycin (100 µg mL⁻¹), and 2 mg mL⁻¹ sodium bicarbonate. The cells were kept in a humidified incubator at 37 °C with a 5% CO₂ atmosphere. To evaluate cell viability, 1.0×10^5 HepG2 cells were plated in each well of a 96-well plate and allowed to incubate for 24 hours. After this initial incubation, the cells were exposed to various concentrations of the OP solvent extracts, specifically at final concentrations of 1, 10, 25, and 50 µg mL⁻¹. Following an additional 72-hour incubation, MTT reagent (5 mg mL⁻¹) was introduced to each well, and the plate was incubated for one more hour at 37 °C. The media were discarded, and the resulting intracellular formazan was dissolved in 100 µL dimethyl sulfoxide (DMSO). The absorbance of each well was recorded at 540 nm using an ELISA reader, and the MTT reduction rate was determined by normalizing the survival rate of the control samples to 100% (Safi *et al.* 2021).

Animal grouping and treatment

The experiments utilizing animal models were done according to the ARRIVE guidelines. To eliminate the risk of pregnancy, the study exclusively involved male Wistar Rats. These subjects were individually housed in polypropylene cages, maintaining a temperature of 21 ± 3 °C and a humidity level of 55%. A 12-hour light/dark cycle was implemented, and the rat had continuous access to a standard laboratory diet and water. Before initiating the experiments, the rat underwent a minimum acclimatization period of one week. Fifteen healthy male Wistar rats were divided into three separate groups: Groups I, II, and III. Group I was treated with cadmium (Cd) at a concentration of 2 mg kg⁻¹ intraperitoneally (Amanpour *et al.* 2024), while Group II received orange peel extract at a dose of 250 mg kg⁻¹ of body weight for 28 days. Group III acted as the control group, receiving only distilled water once daily. The experimental duration extended over eight weeks, with treatment administered at a daily volume of 1 mL via gavage (Akter *et al.* 2022).

Collection of blood samples and male genital organs

After eight weeks, the subjects were euthanized using a CO₂+O₂ chamber. Subsequently, blood samples were collected from the cardia and processed through centrifugation at 3500 rpm for 15 minutes at a temperature of 4°C to isolate the serum. The resulting serum samples were utilized for the assessment of various biochemical parameters, including serum glutamic-pyruvic transaminase (SGPT), alkaline phosphatase (ALP), and aspartate aminotransferase (SGOT) levels. The quantification of SGPT, SGOT, and ALP was performed utilizing commercial assay kits, following the protocols provided by the manufacturers. The testis samples obtained from the rat were subsequently fixed in a 10% formalin solution for further tissue processing. The testis samples collected from the rats were then preserved in a 10%

formalin solution to facilitate subsequent tissue dispensation. Following fixation, these samples were embedded in paraffin, and serial thickness sections measuring 4-6 μm were organized for staining with hematoxylin and eosin (Amanpour *et al.* 2024).

Measurement of oxidative stress biomarkers

The serum total oxidant status (TOS) was assessed using an automated colorimetric method as outlined by Erel. The initial reagent formulation included 150 μM xylenol orange, 140 mM sodium chloride, and 1.35 M glycerol, all dissolved in 25 mM sulfuric acid at a pH of 1.75. The subsequent reagent contained five mM Fe^{3+} and five mM 4-(4-amino-3-methoxyphenyl)-2-methoxyaniline, prepared in 25 mM sulfuric acid. Absorbance measurements were taken at 650 nm after a 3-minute incubation, with a blank sample used as a reference. TOS values were calculated by creating a standard curve and utilizing the regression equation $y = mx \pm b$. The serum samples' total antioxidant capacity (TAC) was evaluated using a spectrophotometric technique, also developed by Erel. The initial reagent for this analysis comprised five mM Fe^{3+} and 10 mM 4-(4-amino-3-methoxyphenyl)-2-methoxyaniline in a Clark and Lubs solution at a concentration of 75 mM and a pH of 1.8. The second reagent was 7.5 mM hydrogen peroxide in the same Clark and Lubs solution. Absorbance was recorded at 440 nm following a 3-minute incubation, again using a blank for calibration. TAC values were determined by establishing a standard curve and applying the regression equation $y = mx \pm b$ (Abod *et al.* 2021).

Statistical analysis

Comparisons among the data were conducted using one-way analysis of variance (ANOVA), followed by independent samples t-test to evaluate mean \pm standard error differences between groups and ascertain the significance level. A p -value of less than 0.05 was considered statistically significant.

RESULTS

Fig. 1 revealed light microscopy images alongside the viability percentages of HepG2 cells after a 72-hour incubation period with varying concentrations of OP (1, 10, 25, and 50 $\mu\text{g mL}^{-1}$). Treatment with OP at a concentration of 1 $\mu\text{g mL}^{-1}$ (100.01 ± 2.21) over three days did not result in cytotoxicity. However, an increase in OP concentration up to 50 $\mu\text{g mL}^{-1}$ led to a gradual decline in cell viability, suggesting a cytotoxic effect associated with higher concentrations of OP. Similarly, the viability of cells treated with OP also decreased across the various concentrations assessed on the 3rd day.

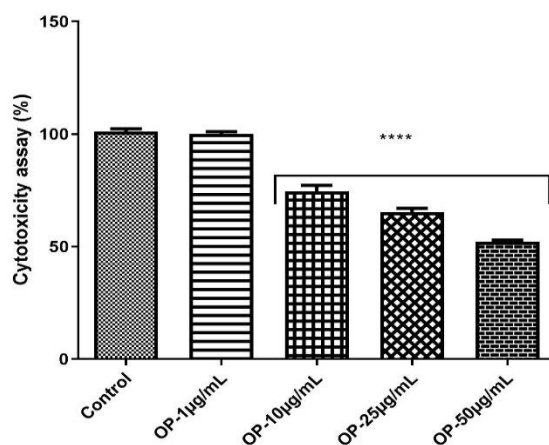


Fig. 1. The HepG2 cells were treated with a range of concentrations of OP (1, 10, 25, and 50 $\mu\text{g mL}^{-1}$) for 72 h, and cell viability percent was measured. The asterisks replicate significant differences with *: $p < 0.05$, **: $p < 0.01$, ***: $p < 0.001$, and ****: $p < 0.0001$.

TOS and TAC level

As illustrated in Fig. 2A, the TAC levels in the treatment group were markedly lower than those detected in the Cd group ($p < 0.0001$). Furthermore, the TAC levels in the group receiving the prescribed extract ($0.81 \pm 0.301 \mu\text{M}$) displayed a significant difference when compared to the control group ($0.23 \pm 0.3 \mu\text{M}$; $p < 0.0001$). The findings presented in Fig. 2B reveal a distinguished rise in TOS levels in the treatment group ($11.48 \pm 0.51 \text{ nM mL}^{-1}$) that received the extract, in contrast to the Cd group ($5.16 \pm 0.54 \text{ nM mL}^{-1}$; $p < 0.0001$). Moreover, rats subjected to the additional treatment demonstrated noteworthy differences from the control group ($p < 0.0001$; Fig. 2).

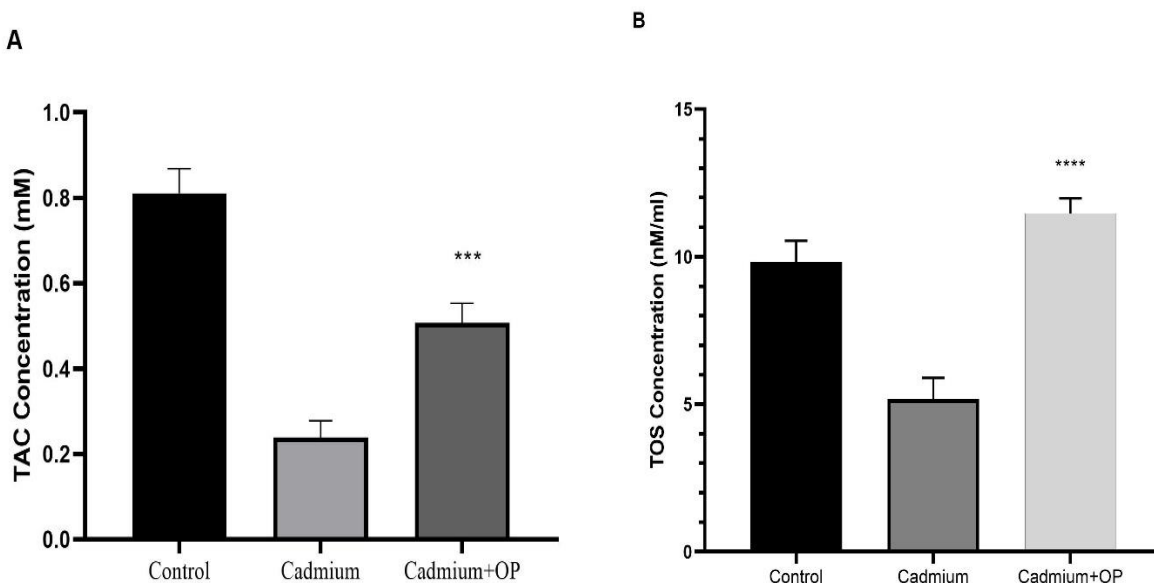


Fig. 2A: TAC activity in sera samples isolated from Cd, Control, and Cd + OP. **Fig. 2B:** TOS activity in sera samples isolated from Cd, Control, and Cd + OP. Data were statistically analyzed using analysis of variances (ANOVA) followed by a post-Tukey test, and a p -value less than 0.05 was considered a significant difference to compare the model group that received Cd without treatment. The asterisks replicate significant differences with *: $p < 0.05$, **: $p < 0.01$, ***: $p < 0.001$, and ****: $p < 0.0001$.

Effect of OP on the biochemical parameters

The influence of OP on hematological and biochemical parameters was assessed. A significant elevation ($p < 0.01$) in the biochemical parameters, including SGPT, SGOT, and ALP, was perceived in the control group compared to the model group. Additionally, the biochemical parameters, including serum SGPT, ALP, and SGOT, decreased across all dosage levels in rats exposed to Cd when treated with OP (Fig. 3).

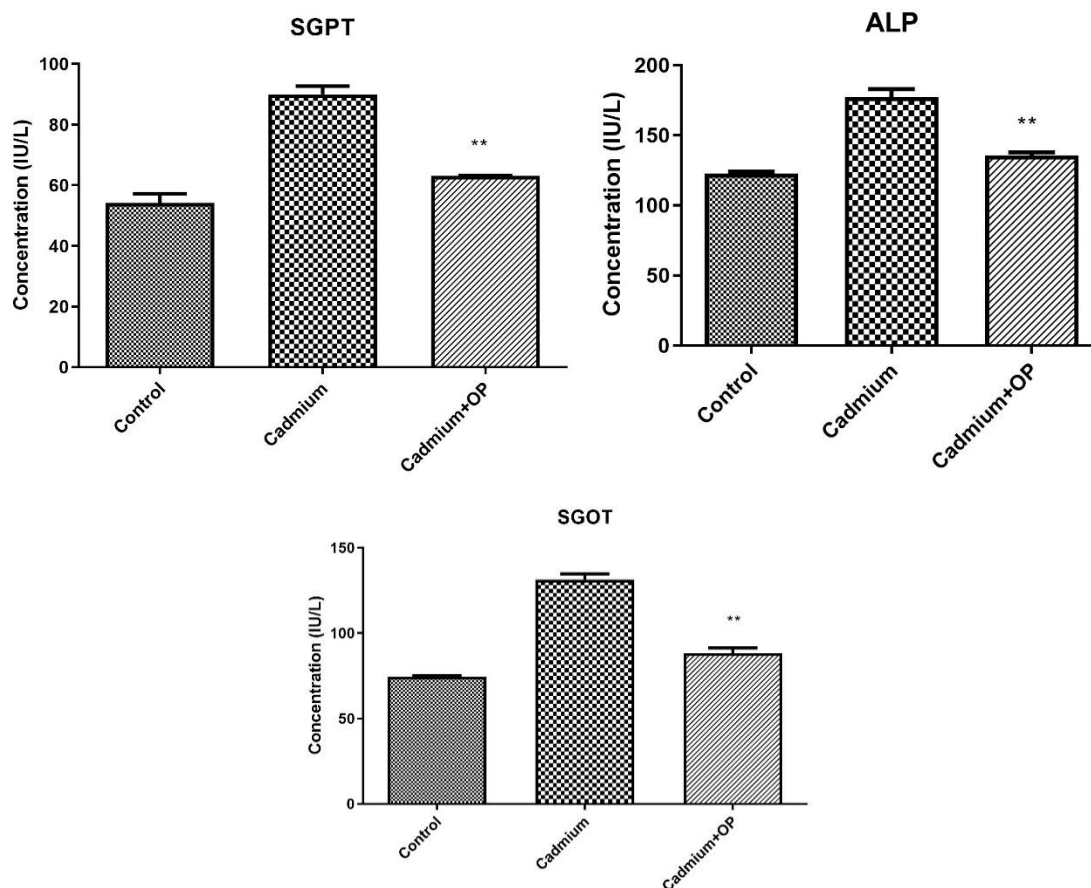


Fig .3. The effects of Cd administration and treatment with OP on the serum level of SGOT, SGPT, and ALP of rat in experimental groups. Data are represented as Mean \pm SD. One-Way ANOVA followed by a post hoc LSD test was used for comparison between different groups. The asterisks replicate significant differences with *: $p < 0.05$, **: $p < 0.01$, ***: $p < 0.001$, and ****: $p < 0.0001$.

Histopathological evaluation of the testis

The testes in the control and OP-received groups exhibit seminiferous tubules filled with numerous germ cells, while Sertoli cells provide support within the tubules. The spermatozoa are located toward the center; in contrast, a prepubertal testis has tiny tubules lacking active cellular proliferation.

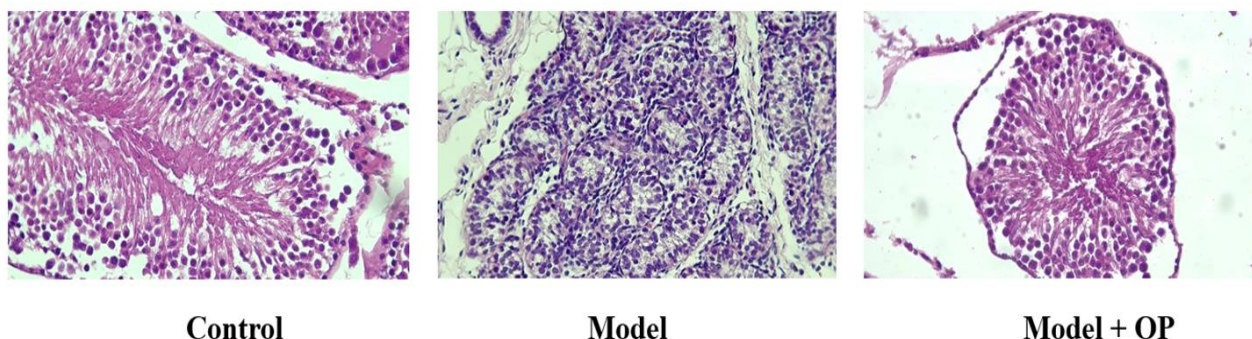


Fig. 4. Histopathological evaluation of three various groups (Control, Model, and Model received OP)

DISCUSSION

This study experimentally explores the effects of orange peel extract supplementation on the toxicity of Cd in rats exposed to this toxin. The results suggest that orange peel extract supplementation may mitigate Cd-induced liver damage by influencing inflammatory responses and biomarkers and increasing antioxidant levels. The methanolic extract derived from orange peels has attracted considerable interest recently due to its potential health benefits and various industrial uses.

Oranges are notable sources of phytochemicals, with their peels particularly rich in flavonoids, potent antioxidants known for their health-promoting properties. Flavonoids such as hesperidin and naringin, found in orange peel, have been associated with numerous health benefits. These compounds exhibit anti-inflammatory and antioxidant effects that may lower the risk of chronic diseases, including cardiovascular conditions and cancer (Afsharnejad *et al.* 2017). Orange peel extracts have been evaluated for their ability to counteract cadmium-induced oxidative stress and toxicity. These extracts are rich in antioxidants, including flavonoids, phenolics, and ascorbic acid, which are crucial in neutralizing free radicals and enhancing the body's antioxidant defense system. Studies have demonstrated that the orange peel extracts can reduce oxidative stress markers and improve antioxidant enzymes in cadmium-exposed organisms. For instance, in a study involving Wistar rats exposed to cadmium, the administration of orange peel extract significantly reduced MDA levels. It restored the activity of antioxidant enzymes, indicating its potential to mitigate oxidative damage. The orange peel extracts have also shown chelating properties, which enable them to bind with cadmium ions and reduce their bioavailability. In one study, the extract decreased cadmium levels in rats' blood, liver, and kidney tissues, suggesting its ability to sequester cadmium and enhance its excretion. Cadmium-induced toxicity often targets the liver and kidneys, leading to enzyme leakage and tissue damage. Orange peel extracts have been shown to protect these organs by reducing liver enzymes (ALT, AST, and ALP) and serum markers of kidney damage (urea, creatinine) in cadmium-exposed rats. These protective effects are attributed to the extract's antioxidant and chelating properties (Ndubuisi *et al.* 2020; Ekhtor *et al.* 2022).

The research conducted by Ekhtor *et al.* demonstrated that the administration of *Citrus sinensis* peel extract (CSPE) led to a significant decrease in malondialdehyde (MDA) levels in the blood, kidneys, and liver tissues of Wistar rats subjected to lead and cadmium exposure, suggesting its potential as an antioxidant agent. Notably, MDA levels in the lead-exposed group were markedly elevated compared to the control and the treated groups. In contrast, those receiving CSPE exhibited a dose-dependent decline in MDA concentrations. Furthermore, the cadmium and lead concentrations in the blood, kidneys, and liver tissues were significantly lower in rats administered 500 mg kg⁻¹ CSPE, indicating its chelating properties. The findings also revealed that, although there was no significant difference in cadmium levels between the model and the treatment group, all treated groups, particularly the one receiving 500 mg kg⁻¹ CSPE, showed a reduction in cadmium levels relative to the untreated Cd group (Ekhtor *et al.* 2022).

The research conducted by Ndubuisi *et al.* in 2020 revealed notable variations in liver enzyme concentrations (AST, ALT, and ALP) and serum total protein levels when contrasting the positive control group, which was administered cadmium chloride, with the normal control group. This suggests that exposure to cadmium resulted in hepatic injury and oxidative stress. Furthermore, administering the aqueous extract of OP at a high dosage of 40 mg kg⁻¹ body weight demonstrated both ameliorative and protective effects against liver toxicity induced by cadmium. This was supported by histological enhancements and a decrease in oxidative stress markers relative to the positive control group (Ndubuisi *et al.* 2020).

The research of Akinhanmi *et al.* in 2020 indicated that the waste orange peel (OP) serves as an efficient and economical adsorbent for extracting Cd ions from water. The adsorption process was characterized as endothermic, with an enthalpy change of 0.0046 kJ mol⁻¹ and a negative entropy of -636.865 J mol⁻¹·K⁻¹, indicating that increased temperatures enhance the adsorption efficiency (Akinhanmi *et al.* 2020).

Cadmium (Cd) is recognized as an endocrine disruptor because it disrupts the production of hormones essential for reproductive health. This metal has found extensive application in numerous sectors, such as the manufacturing of batteries, the production of pigments, the stabilization of plastics, electroplating, coating processes, and the creation of alloys. Cd is released into the environment, accumulating in soil and vegetation, particularly cereal crops. The testes are identified as critical organs for assessing Cd accumulation (Genchi *et al.* 2020). A multitude of studies has demonstrated that Cd exposure can inflict significant harm on the testes, leading to conditions such as testicular atrophy, hemorrhage, edema, necrosis, and reductions in sperm motility, and testosterone production (Li *et al.* 2019).

In our study, the use of OP led to a noteworthy reduction in serum SGOT levels compared to the Cd group. Additionally, the serum SGPT levels in the group treated with the extract were markedly lower than those recorded in the Cd group. The extract administration also resulted in a substantial reduction in ALP concentration when contrasted with the model group. Moreover, there was a decline in TAC and an elevation in TOC following the oral intake of OP. Histopathological evaluations indicated an enhancement in testis architecture that had been adversely affected by Cd exposure. The protective effects of male reproduction are largely attributed to its antioxidant, anti-inflammatory, and anti-carcinogenic properties. The extract's capacity to mitigate oxidative stress, inhibit inflammatory pathways, and restore testis functionality underscores its potential as a natural agent for testis protection.

CONCLUSION

The investigation revealed that the methanolic extract derived from orange peels significantly alleviated the toxic impacts of cadmium in rat models. This conclusion was supported by restoring altered biochemical markers in rats exposed to cadmium, indicating the extract's detoxifying capabilities. The administration of orange peel extract led to a substantial decrease in serum levels of liver enzymes, including SGOT, SGPT, and ALP, which had been elevated due to cadmium toxicity. This finding implies that the extract exerts a protective influence on liver function. Histological assessments indicated improvements in the structural integrity of testicular tissue that had been negatively affected by cadmium exposure. The extract antioxidant, anti-inflammatory, and anti-carcinogenic properties were identified as significant contributors to the restoration of testicular functionality. The research suggests that including orange peel extract in dietary regimens or its use as a complementary approach to chelation therapy may offer health benefits, particularly in addressing cadmium toxicity.

These results emphasize the necessity of investigating natural products such as orange peel extract as potential therapeutic agents against heavy metal-induced toxicity, underscoring their significance in enhancing male reproductive health and overall wellness. In summary, the study presents strong evidence for the protective effects of orange peel extract against cadmium toxicity, indicating its potential utility in health interventions to mitigate heavy metal exposure.

REFERENCES

- Abod, KS, Mohammed, MT & Taay, YM 2021, Evaluation of total oxidant status and antioxidant capacity in acute- and chronic-renal failure patients sera. *Journal of Physics: Conference Series*, IOP Publishing, 12038.
- Afsharnezhad, M, Shahangian, SS, Panahi, E & Sariri, R 2017, Evaluation of the antioxidant activity of extracts from some fruit peels. *Caspian Journal of Environmental Sciences*, 15: 213-222.
- Akachukwu, D, Chukwu, CN, Ojmelukwe, PC, Egbuonu, ACC, Ubiom, IC & Uchegbu, RI 2024, Phytochemical composition of ethanol extract of *Bryophyllum pinnatum* leaves (EEBP) with its effects on haematopoietic indices and bone marrow histology of Cadmium-intoxicated Rats. *Journal of Chemical Health Risks*, 14(4).
- Akinhanmi, TF, Ofudje, EA, Adeogun, AI, Aina, P & Joseph, IM 2020, Orange peel as low-cost adsorbent in the elimination of Cd(II) ion: kinetics, isotherm, thermodynamic and optimization evaluations. *Bioresources and Bioprocessing*, 7(1): 34.
- Akter, R, Neelotpol, S & Kabir, MT 2022, Effect of *Allium sativum* methanol extract in ameliorating arsenic-induced toxicity in *Swiss albino* mice. *Phytomedicine Plus*, 2(1): 100192.
- Amanpour, P, Eftekhari, Z, Eidi, A & Khodarahmi, P 2024, Ameliorative mechanism of dietary vitamin d and magnesium on newborn's pulmonary toxicity induced by cadmium. *Journal of Trace Elements in Medicine and Biology: Organ of the Society for Minerals and Trace Elements (GMS)*, 84: 127469.
- Antar, S, Aymen, H, Gad, C & Al-Karmalawy, A 2023, An Overview of the mechanisms of Cadmium-induced toxicity in the male reproductive system. *Pharmaceutical Sciences*, 30.
- Eagderi, S, Mojazi Amiri, B, Poorbagher, H, Nasrollah Pourmoghadam, M & Nemati Mobin, N 2017, Effects of cadmium on morphological structure of sperm in *Caspiomyzon wagneri* (Kessler, 1870)(Petromyzontiformes: Petromyzontidae). *Caspian Journal of Environmental Sciences*, 15:125-134.

- Ekhtator, O, Prosper, O, Blessing, A, Jessica, E, Aghedo, O, Omozuwa, PO & Chiamaka, E 2022, Antioxidant and chelating effect of *Citrus Sinensis* peel extract on Wistar rats administered with lead and cadmium. *Journal of Biological Research*, 20: 1638-1648.
- Fahim, YA, Hasani, IW, El-Khawaga, AM, Abdelhakim, HK, Sharaf, NE & Lasheen, NN 2024, Occupational exposure to heavy metal dust and its hazardous effects on non-ferrous foundry workers' Health. *Journal of Chemical Health Risks*, 14(3).
- Genchi, G, Sinicropi, MS, Lauria, G, Carocci, A & Catalano, A 2020, The effects of cadmium toxicity. *International Journal of Environmental Research and Public Health*, 17(11): 3782.
- Hayat, MT, Nauman, M, Nazir, N, Ali, S & Bangash, N 2019, Environmental hazards of cadmium: past, present, and future. *Cadmium Toxicity and Tolerance in Plants*, 163–183.
- Ikokide, EJ, Oyagbemi, AA & Oyeyemi, MO 2022, Impacts of cadmium on male fertility: Lessons learnt so far. *Andrologia*, 54(9): e14516.
- Järup, L 2002, Cadmium overload and toxicity. *Nephrology Dialysis Transplantation*, 17: 35-39.
- Li, X, Guo, J, Jiang, X, Sun, J, Tian, L, Jiao, R, Tang, Y & Bai, W 2019, Cyanidin-3-O-glucoside protects against cadmium-induced dysfunction of sex hormone secretion via the regulation of hypothalamus-pituitary-gonadal axis in male pubertal mice. *Food and Chemical Toxicology: An International Journal Published for the British Industrial Biological Research Association*, 129: 13–21.
- Mohamed, NAE, Tohamy, AA & Elgamal, B 2014, Ameliorative effect of citrus peel extract on castration-induced oxidative stress in liver and kidney of rats. *Journal of Applied Pharmaceutical Science*, 4(7): 64-68.
- Ndubuisi, A, Ani, C, Eze, W, Ugwuodike, P, Anyaeji, P, Ude, V, Francis, A, Nworgu, C, Ikwuka, D, Ugwuishi, E & Nwachukwu, D 2020, The effect of aqueous extract of zest of *Citrus sinensis* (AEZCs) on cadmium chloride induced liver toxicity in wistar rats. *African Journal of Biochemistry Research*, 14:5–17.
- Park, J-H, Lee, M & Park, E 2014, Antioxidant activity of orange flesh and peel extracted with various solvents. *Preventive Nutrition and Food Science*, 19: 291–298.
- Safi, A, Heidarian, E & Ahmadi, R 2021, Quercetin synergistically enhances the anticancer efficacy of docetaxel through induction of apoptosis and modulation of PI3K/AKT, MAPK/ERK, and JAK/STAT3 signaling pathways in MDA-MB-231 breast cancer cell line TT. *IJMCMD*, 10: 11–22.